

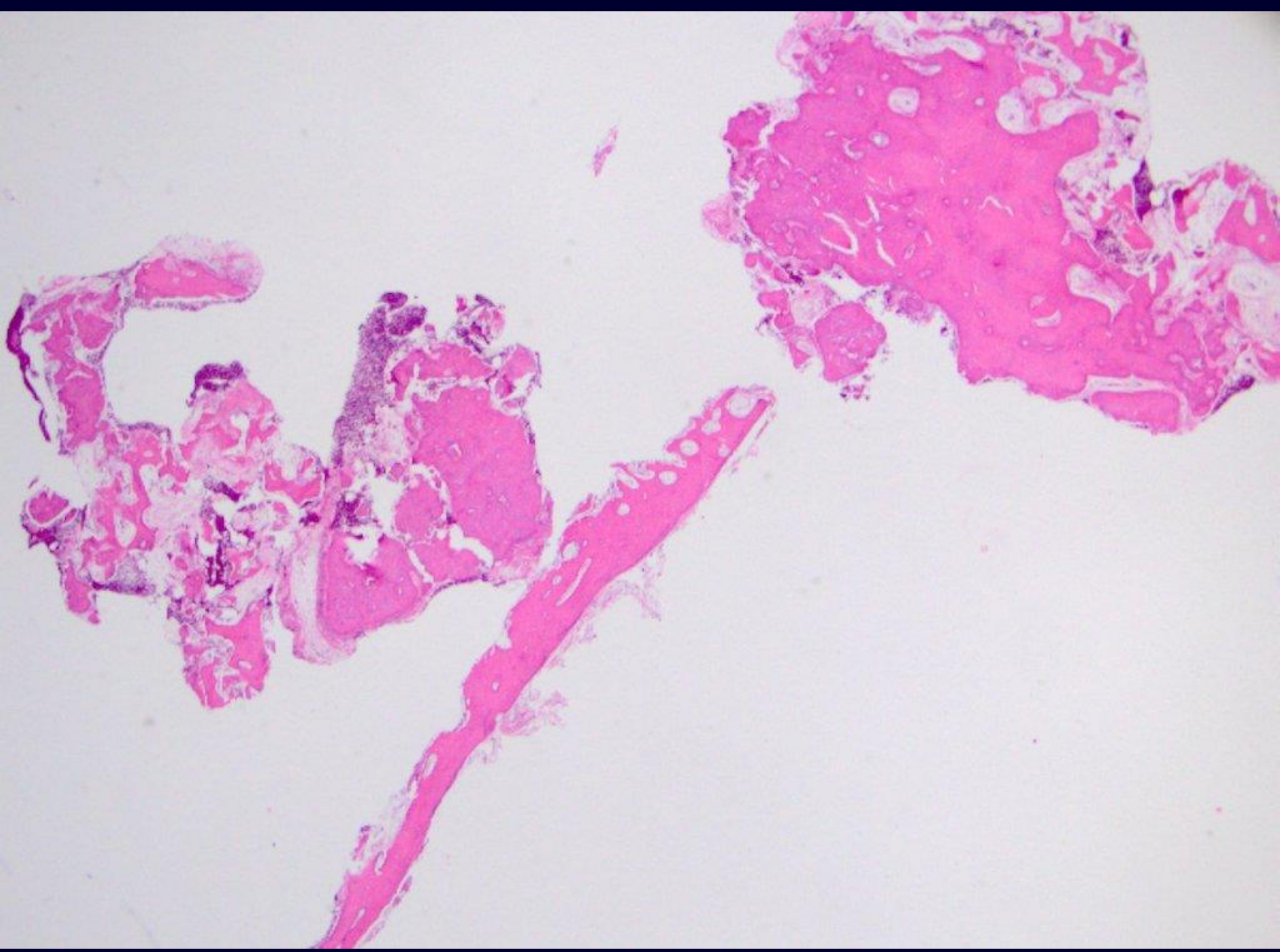
Oral Histopathology

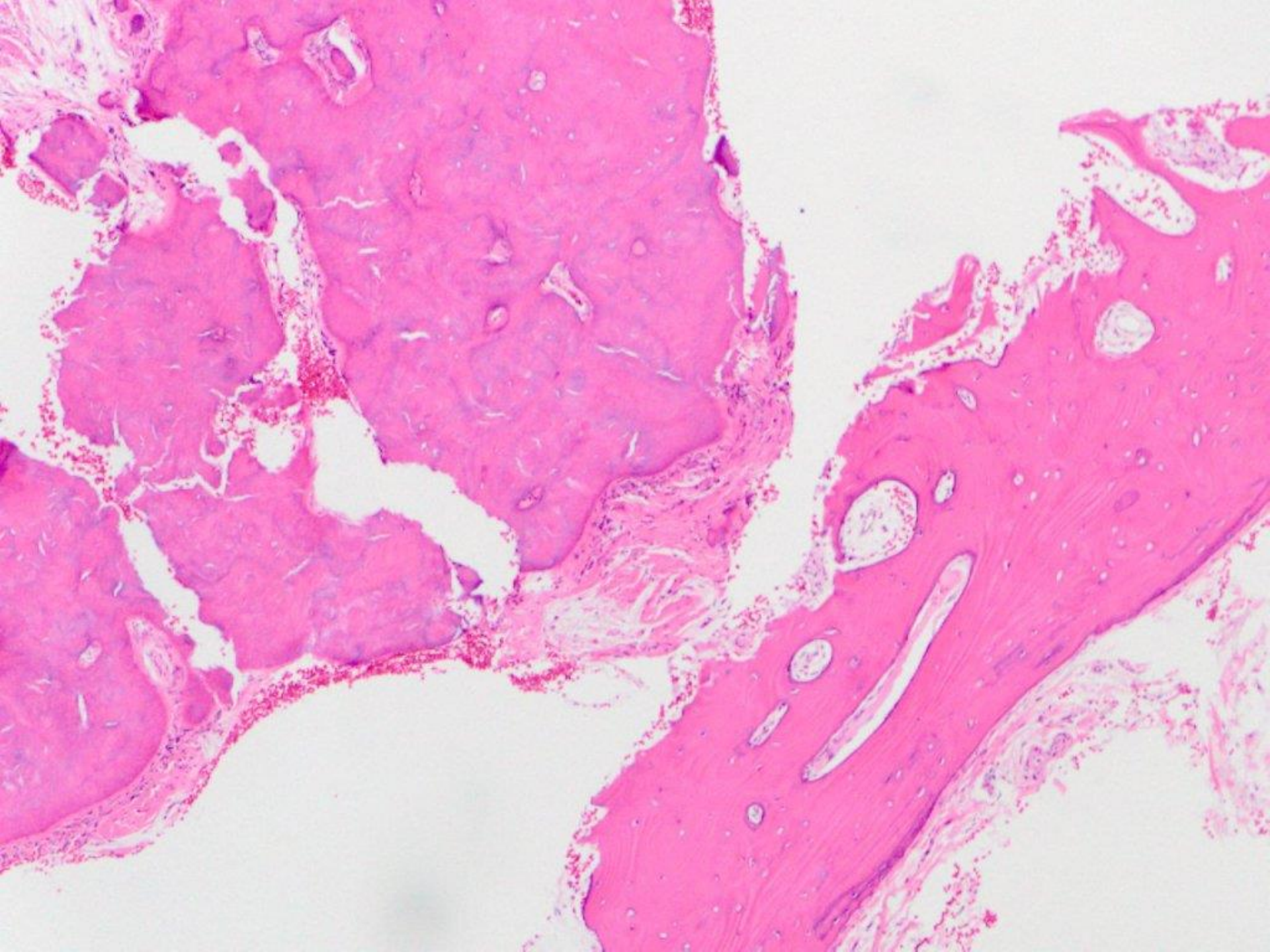
Series 38

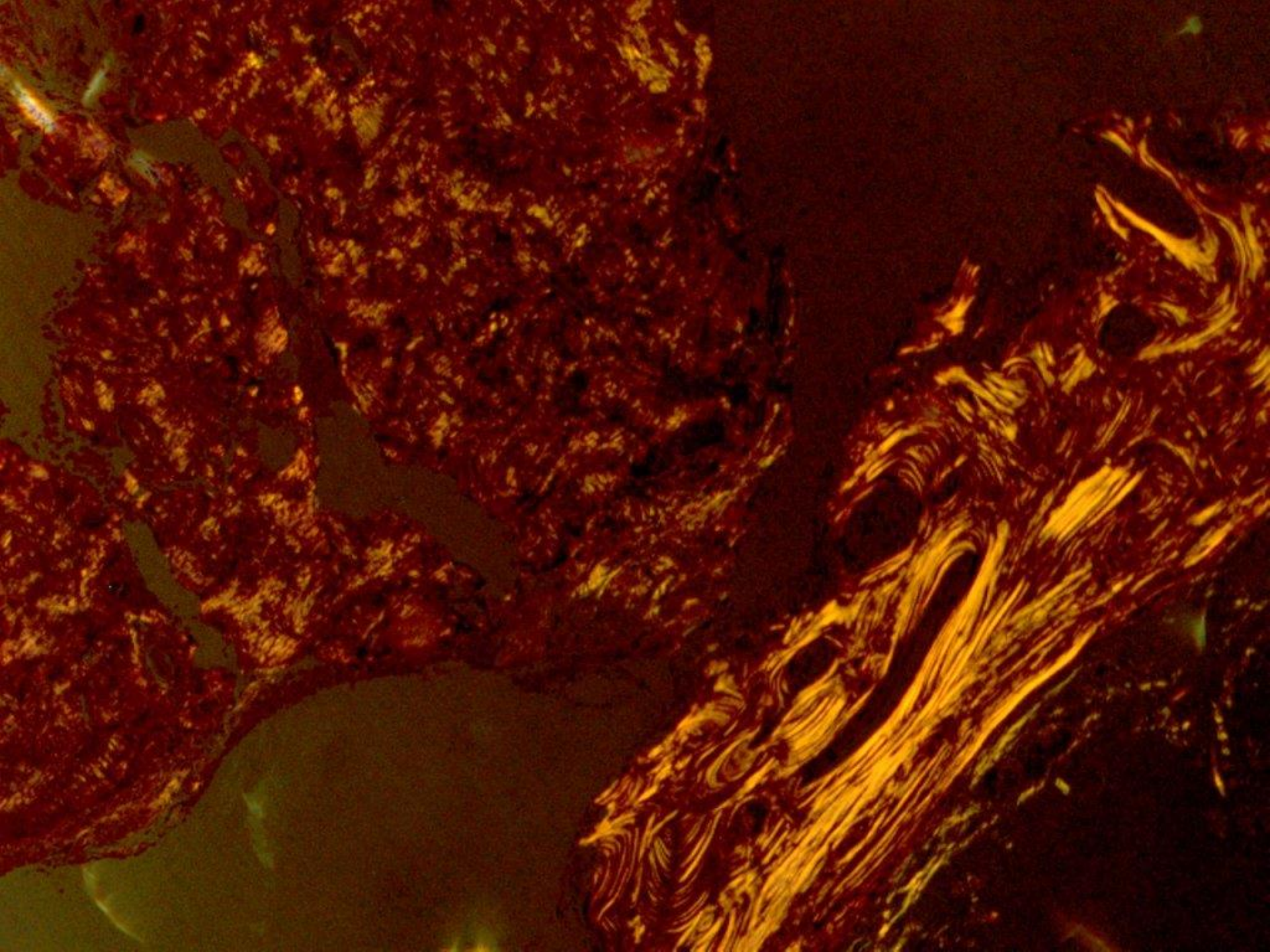
DAVID E. KLINGMAN, DMD

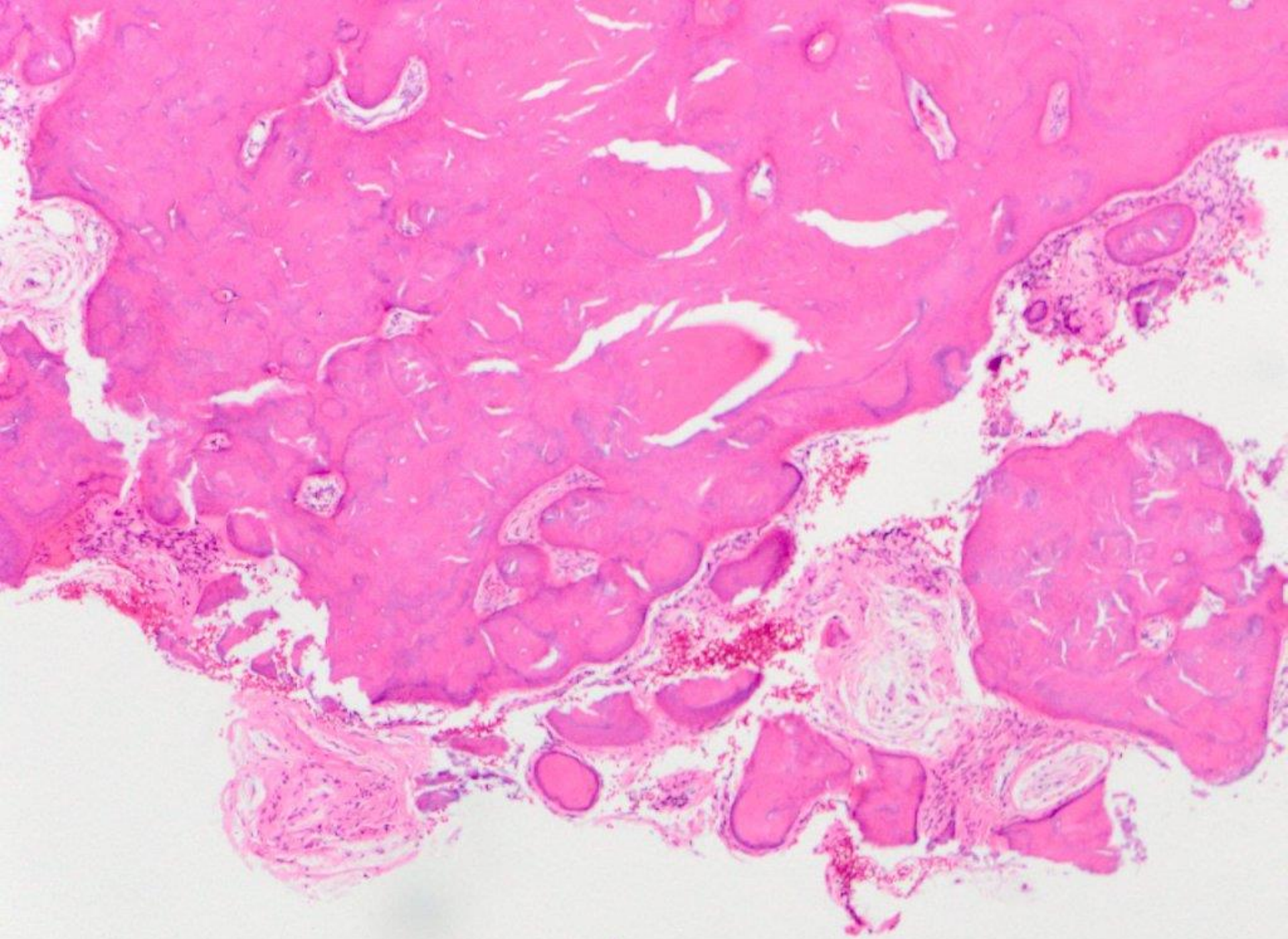
Diplomate, American Board of Oral and Maxillofacial Pathology

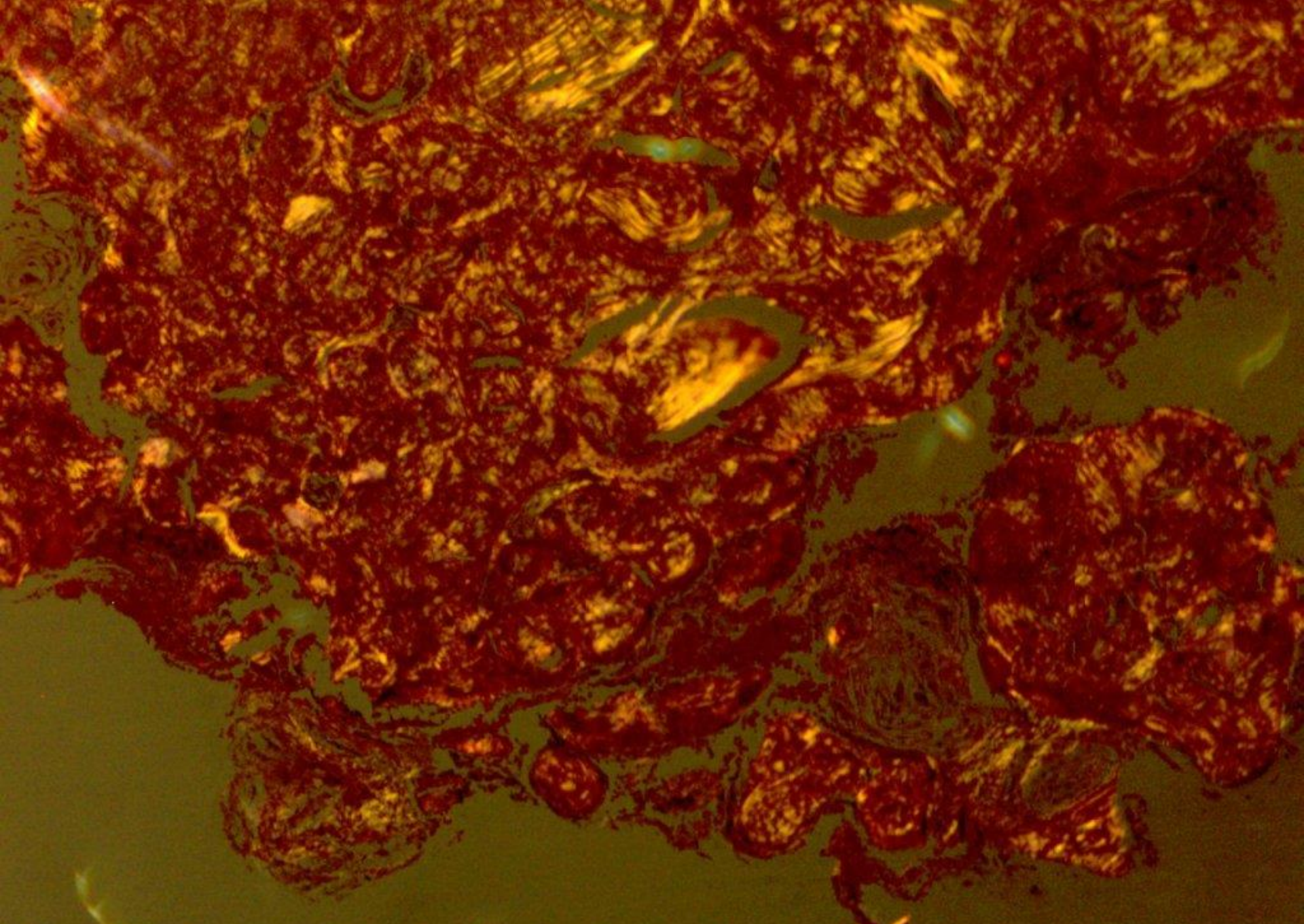
Diplomate, American Board of General Dentistry



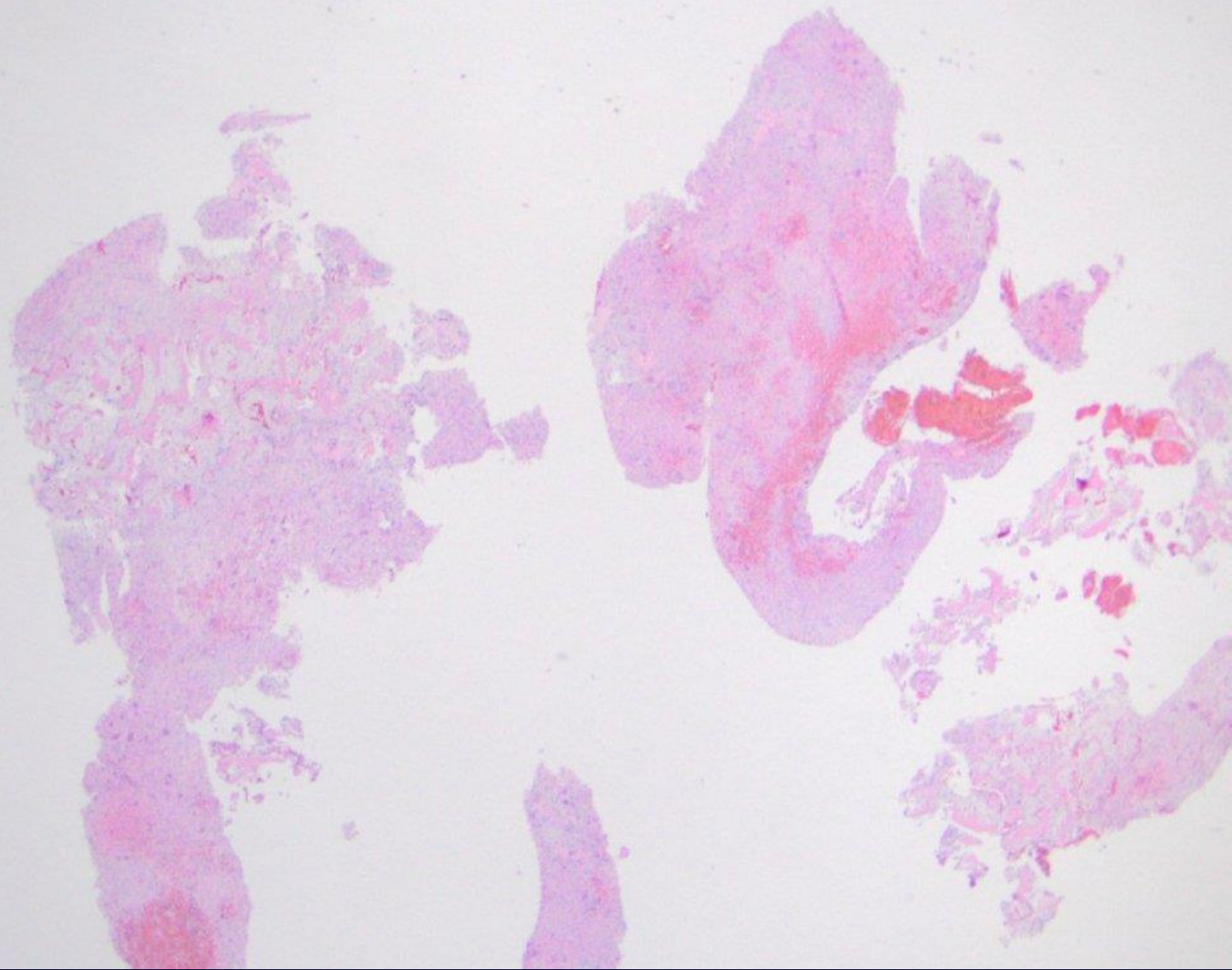


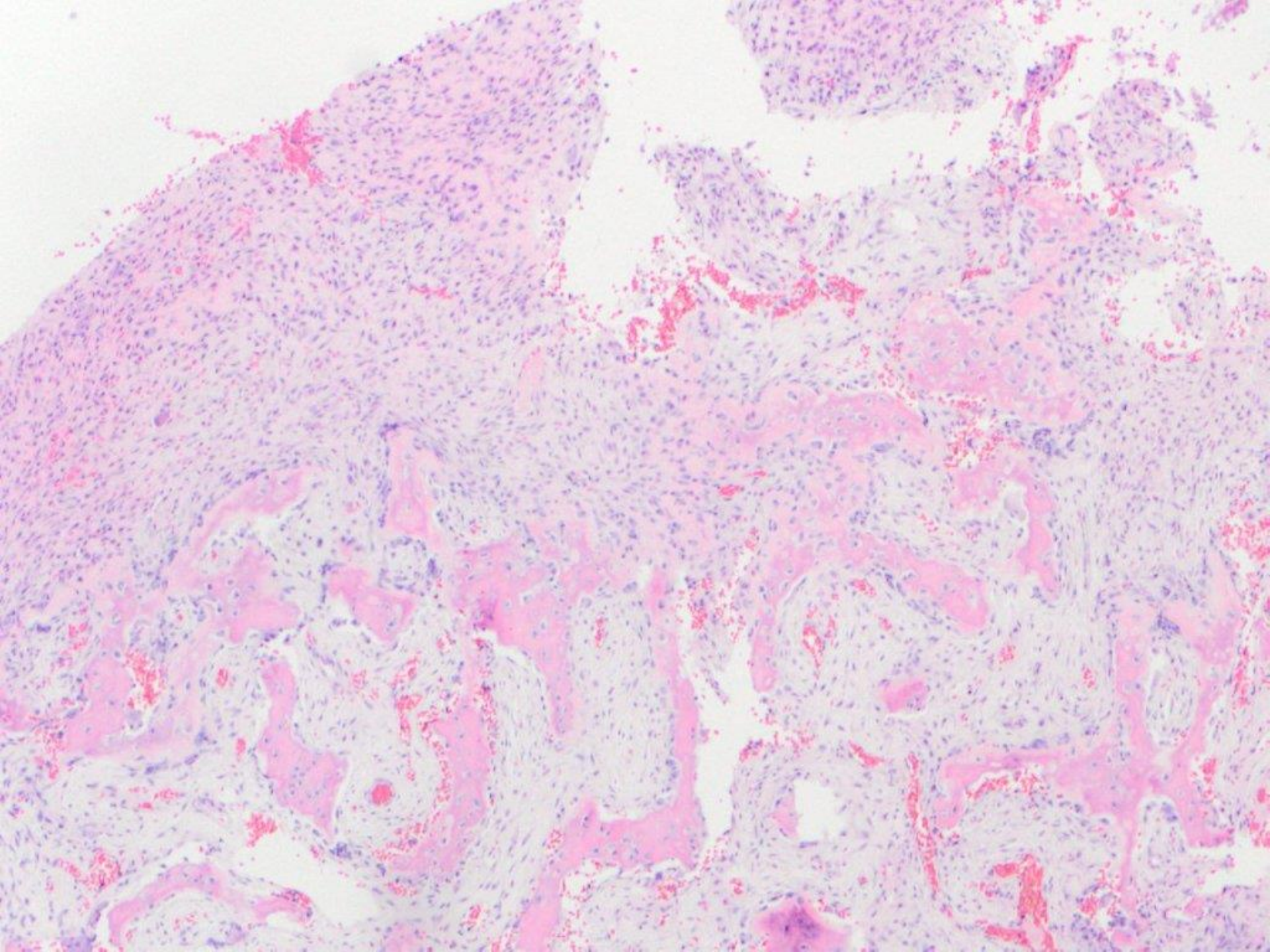


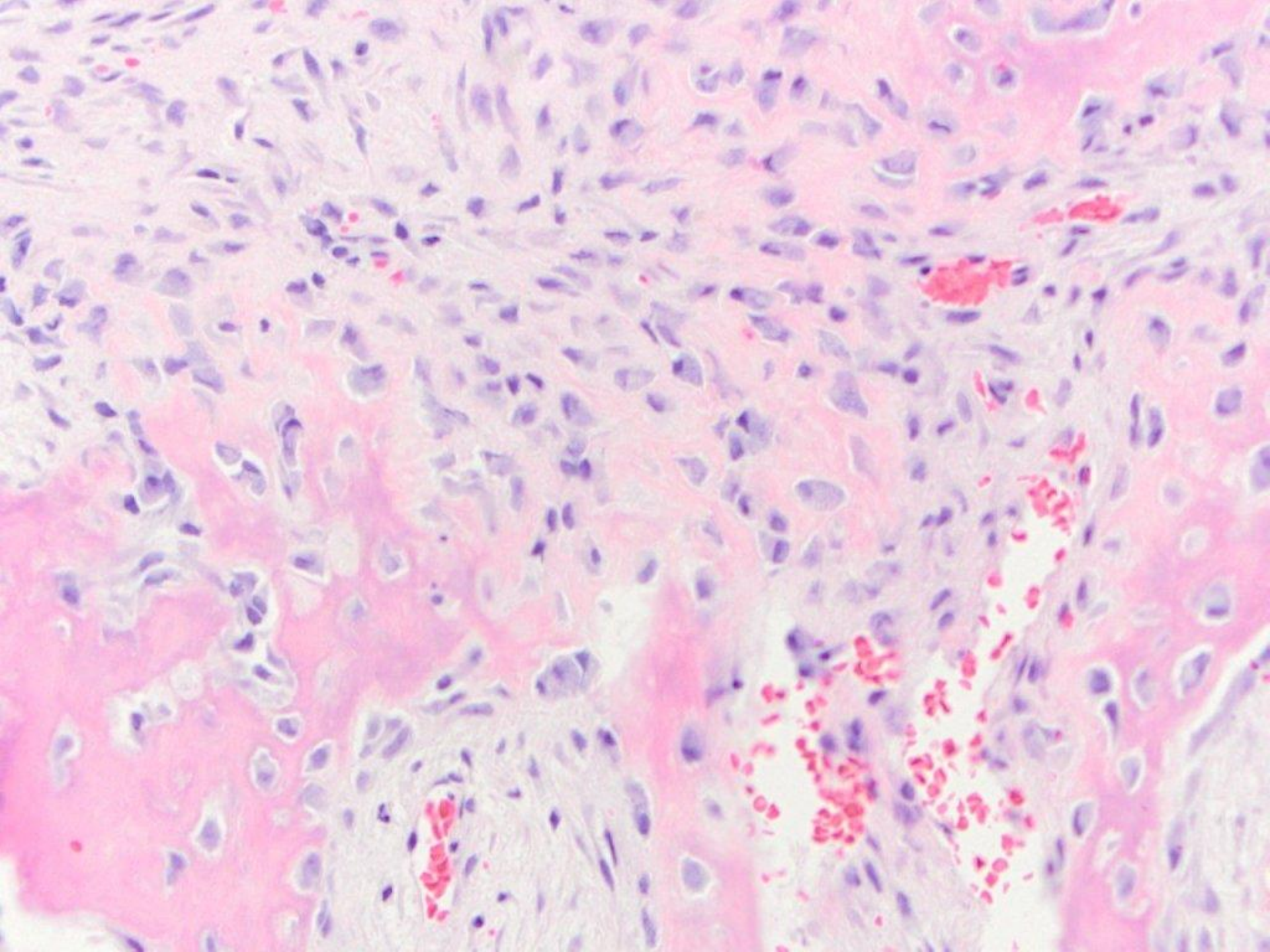


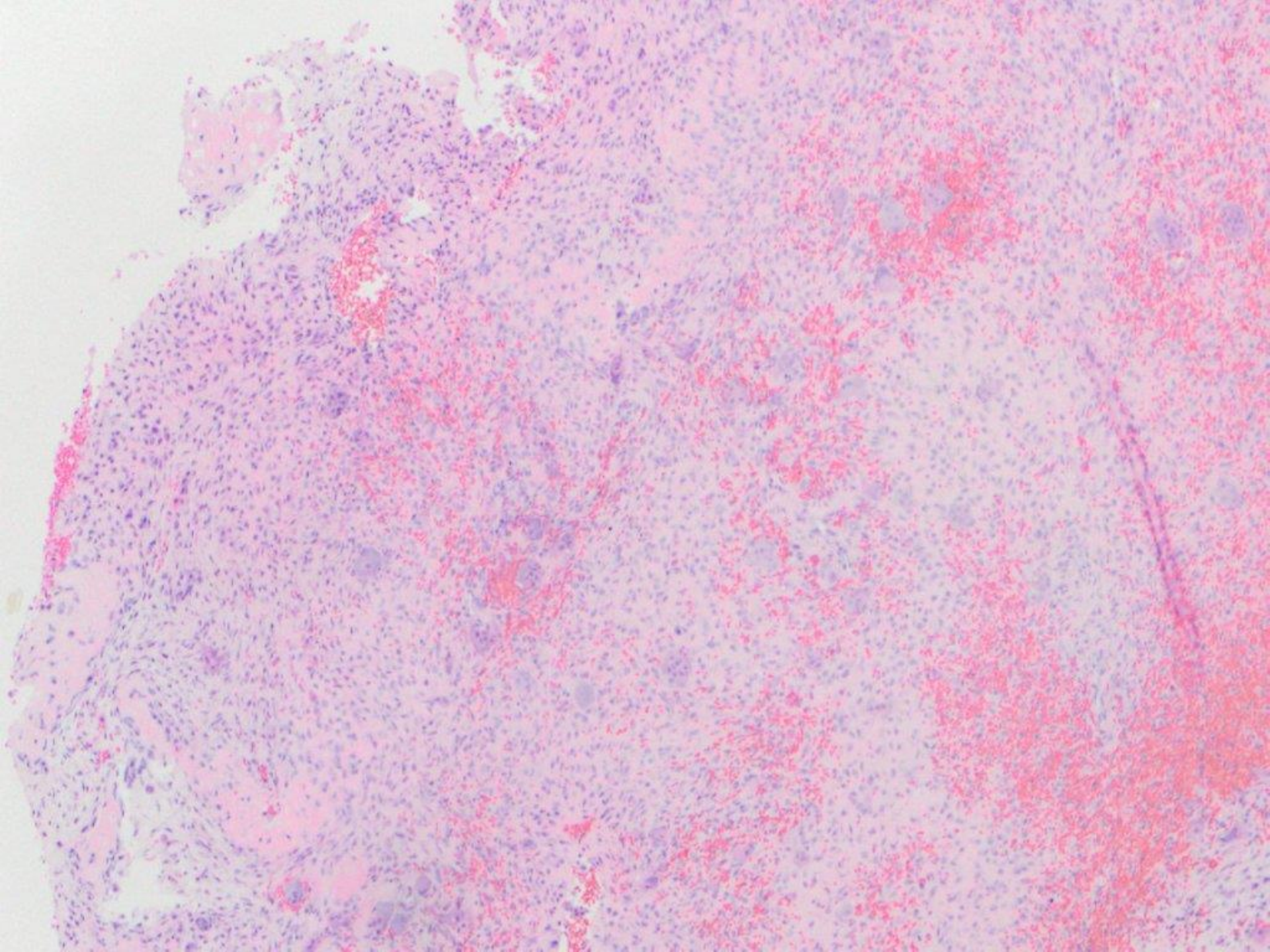


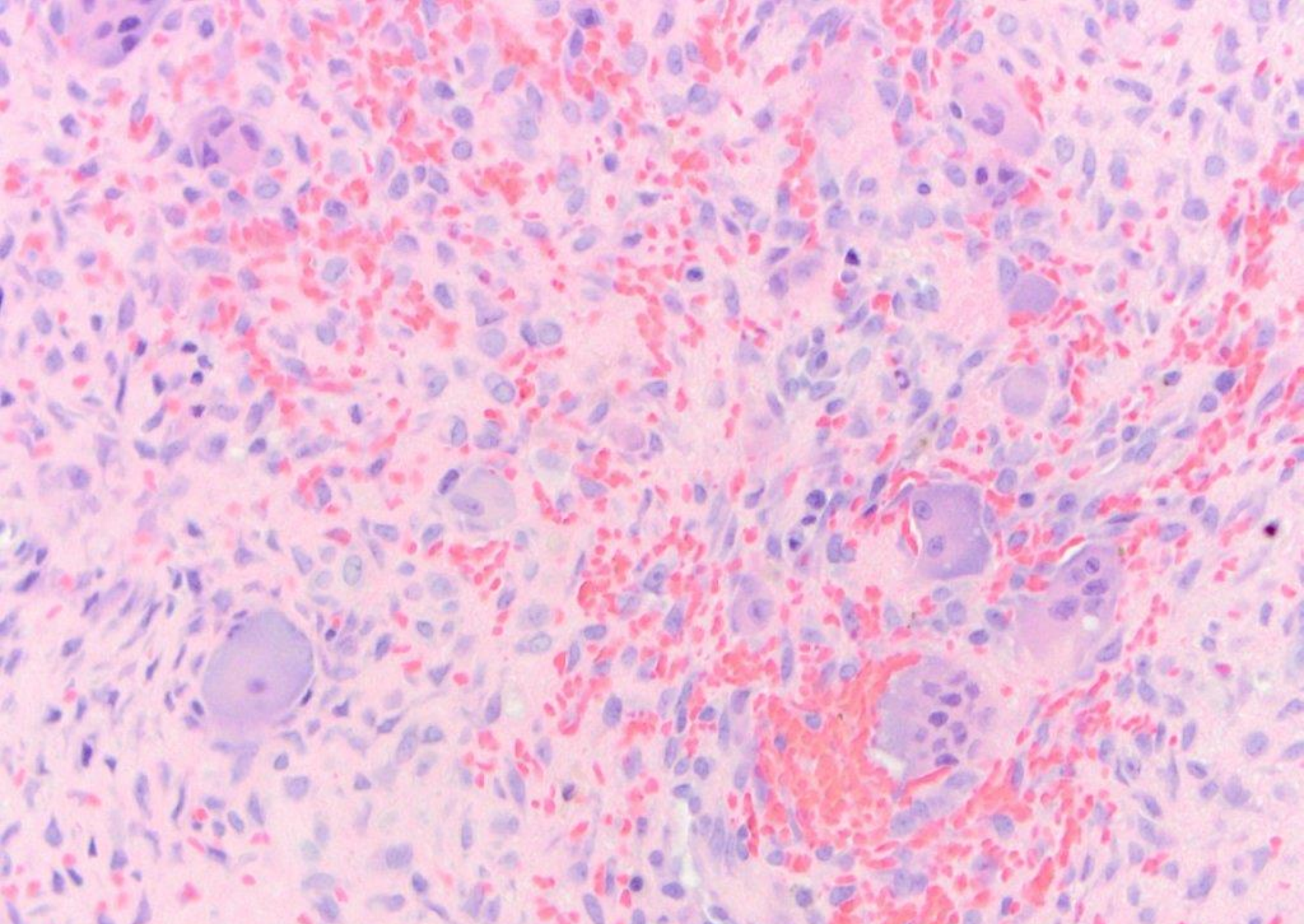
benign fibro-osseous lesion consistent with focal cemento-osseous dysplasia



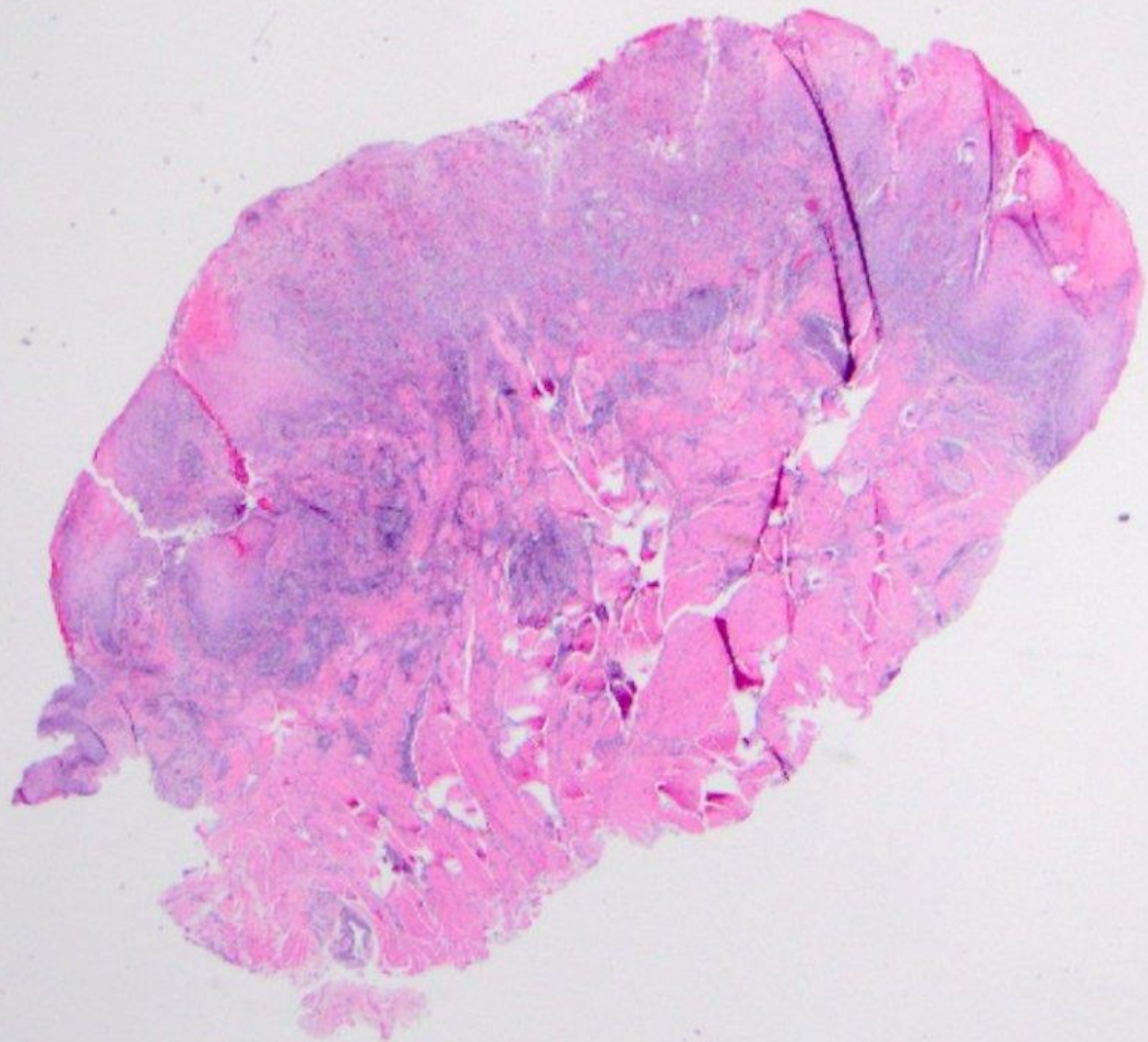


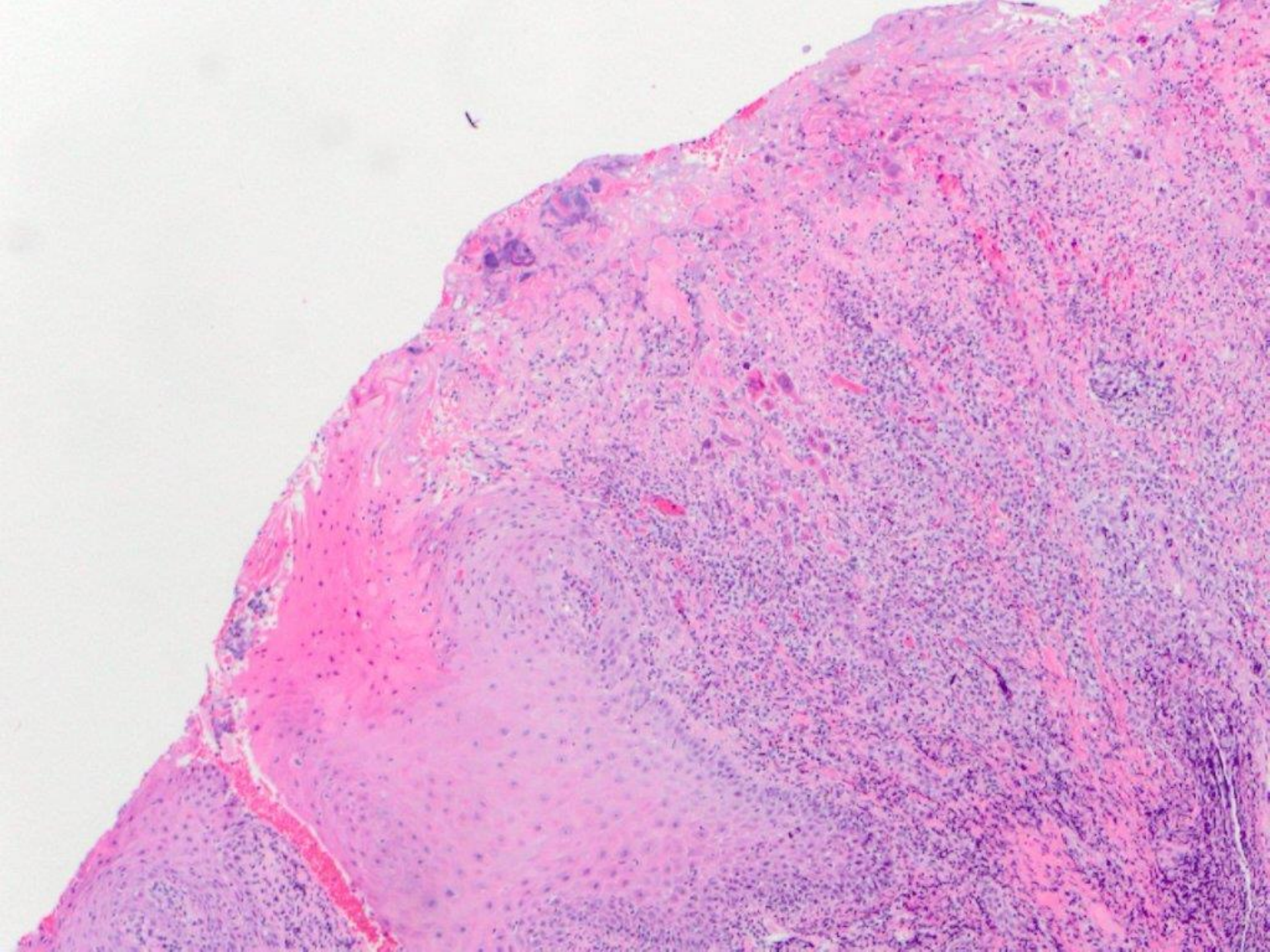


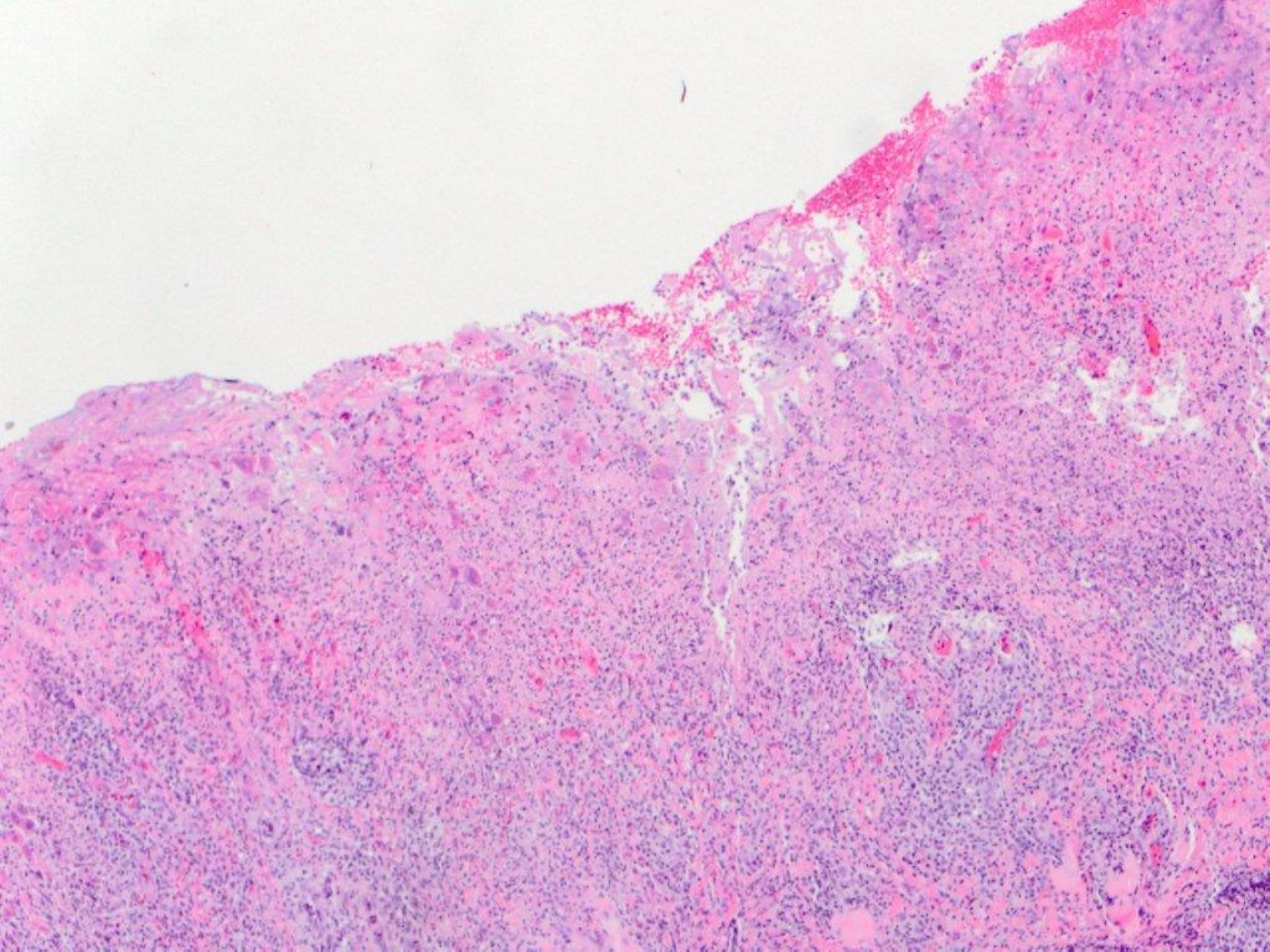


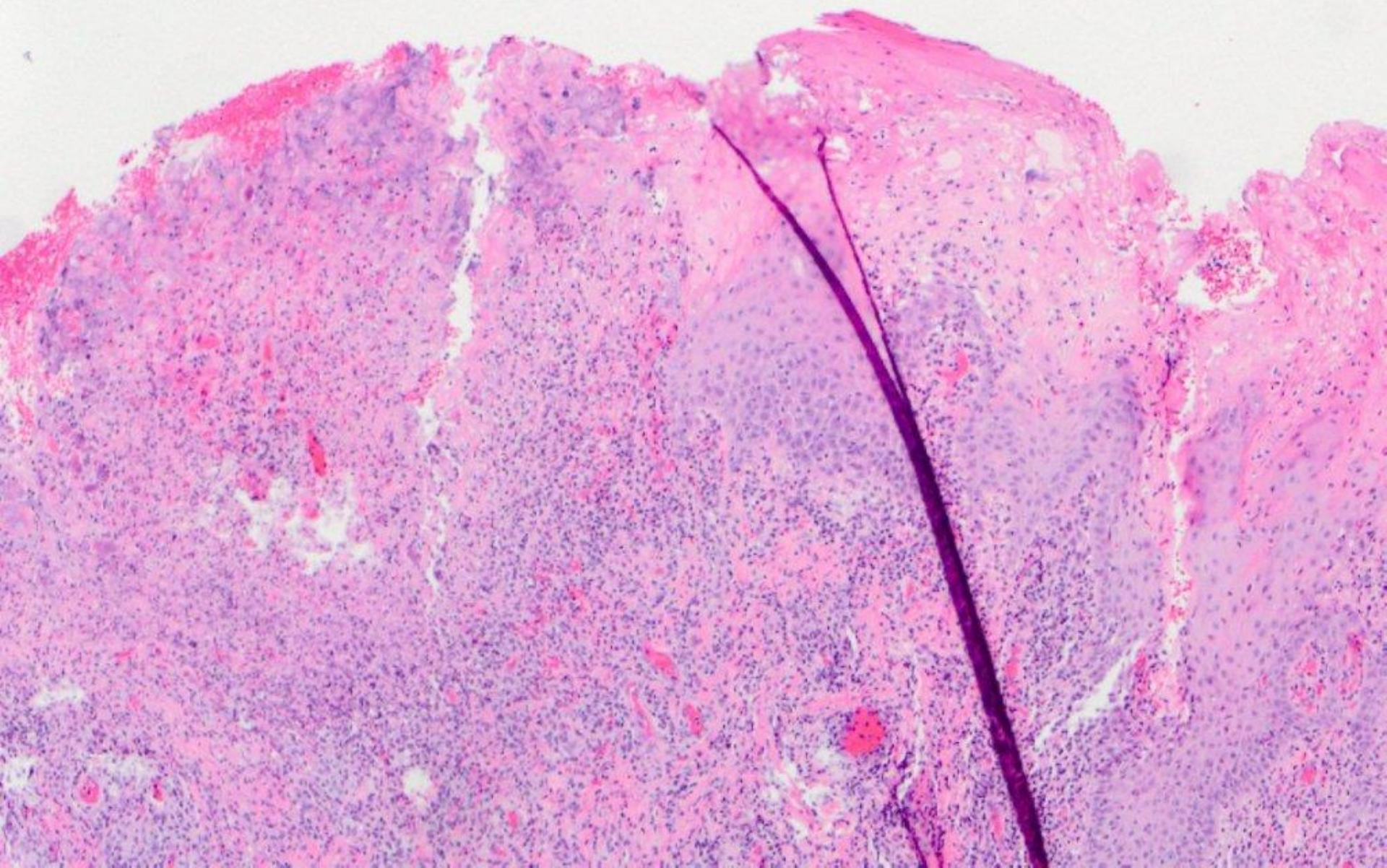


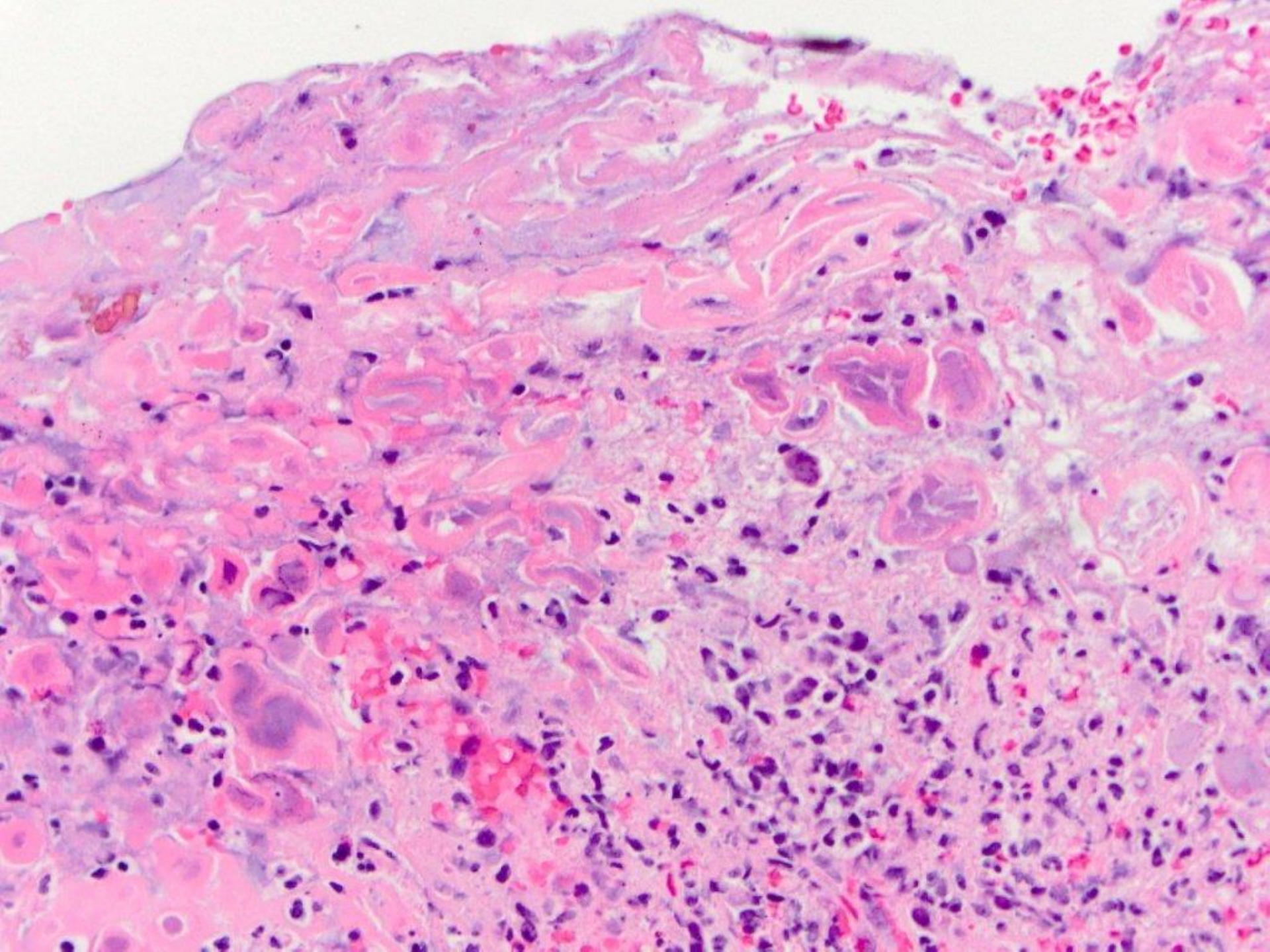
central giant cell granuloma

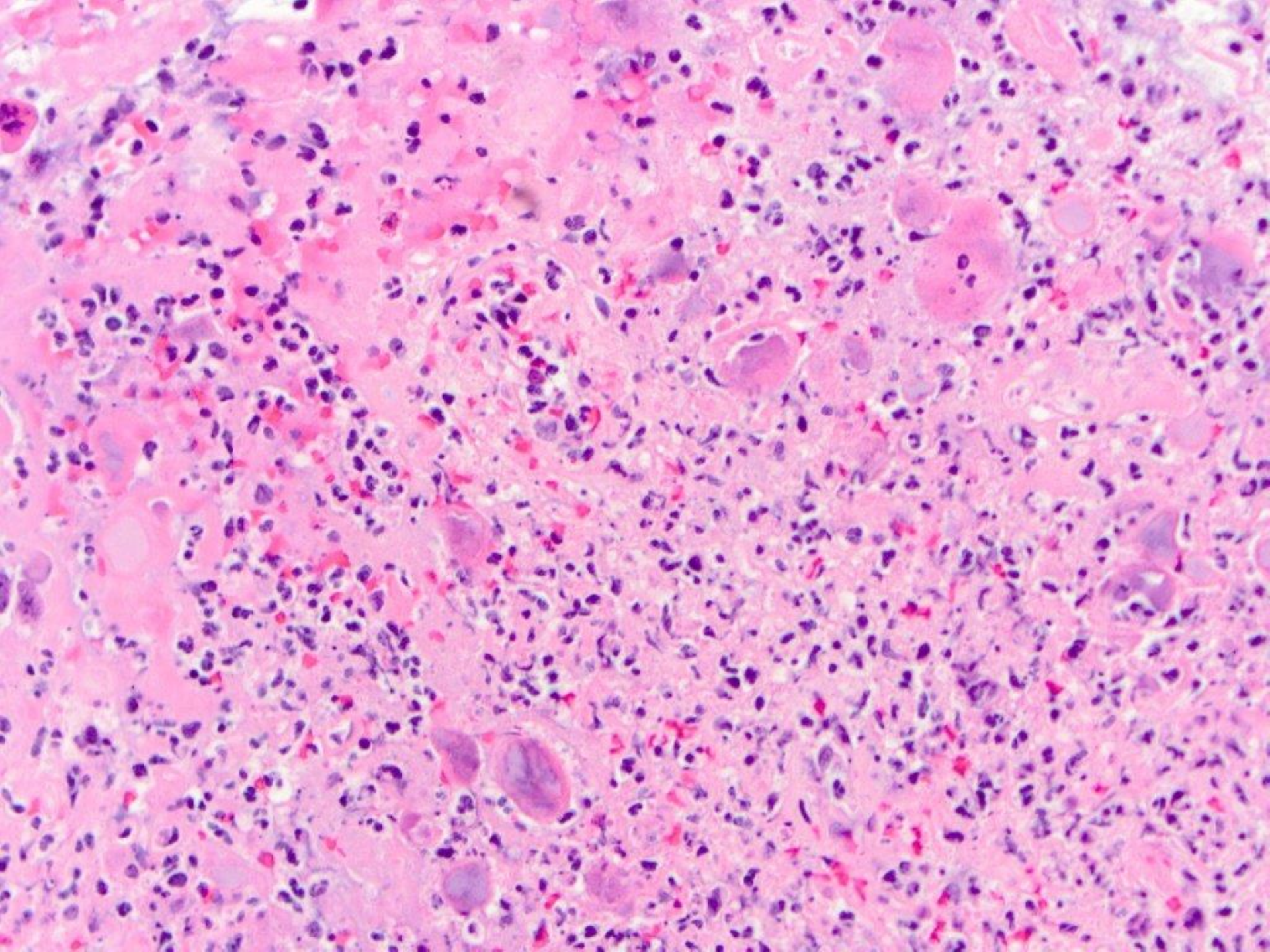


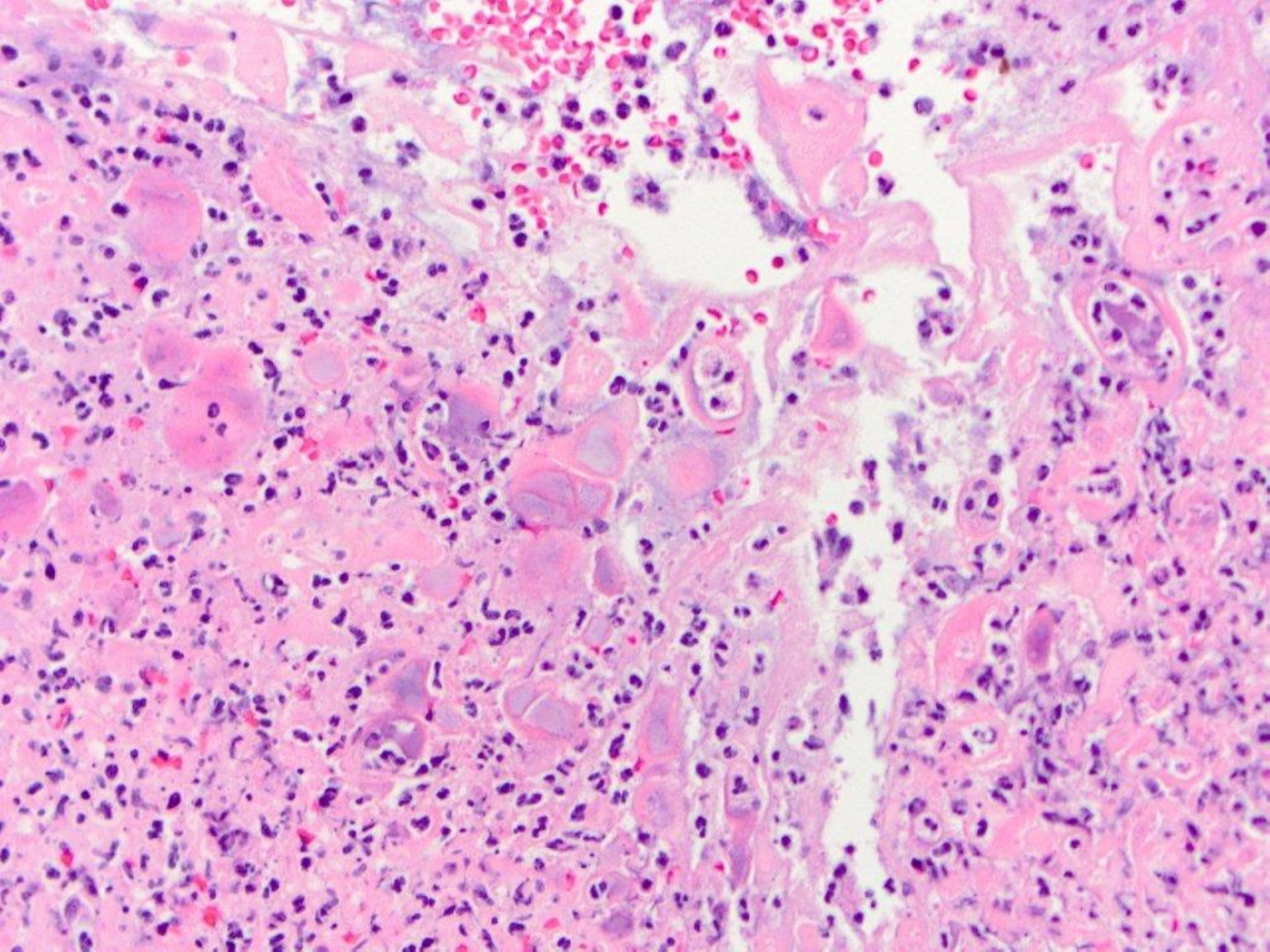


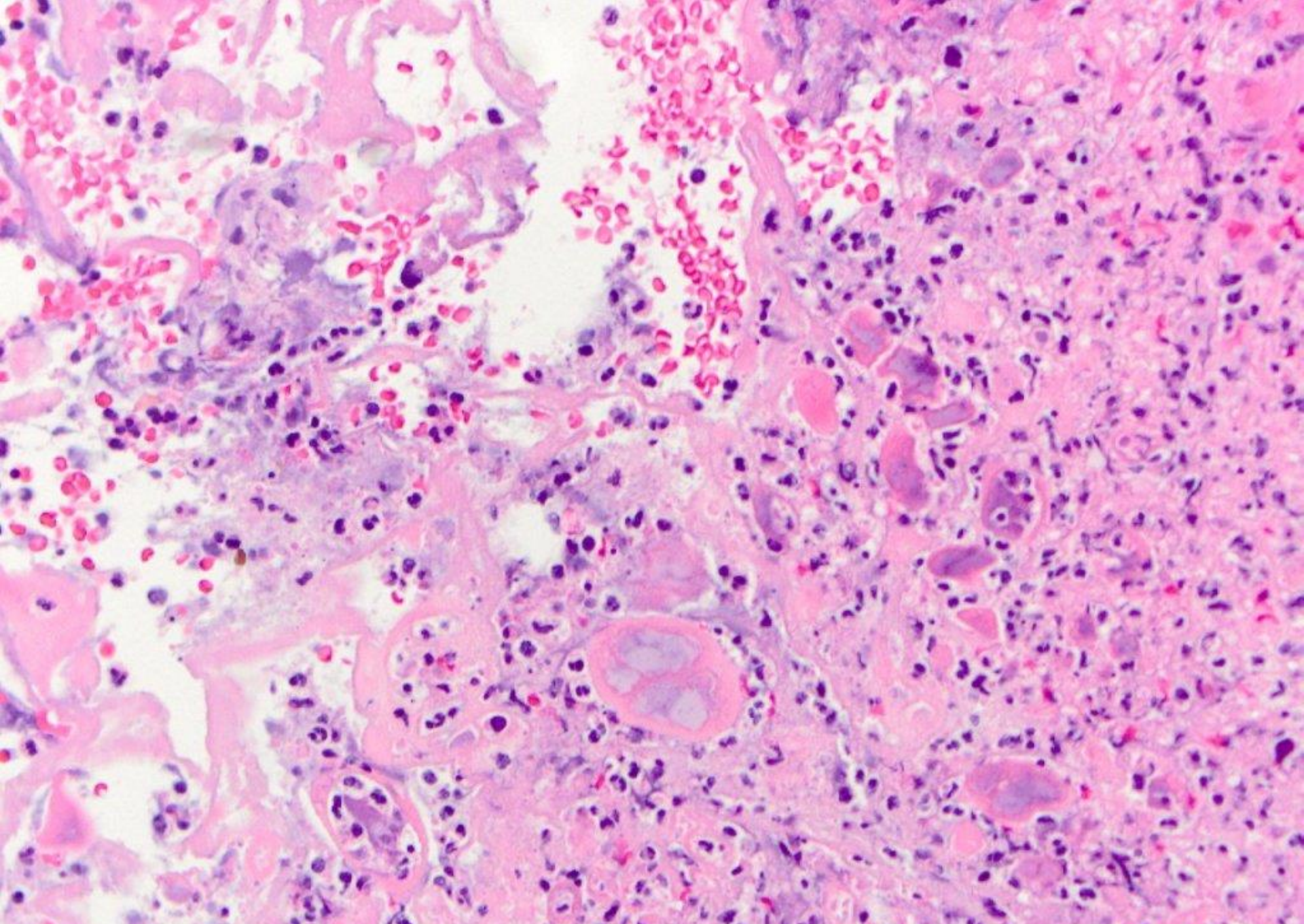




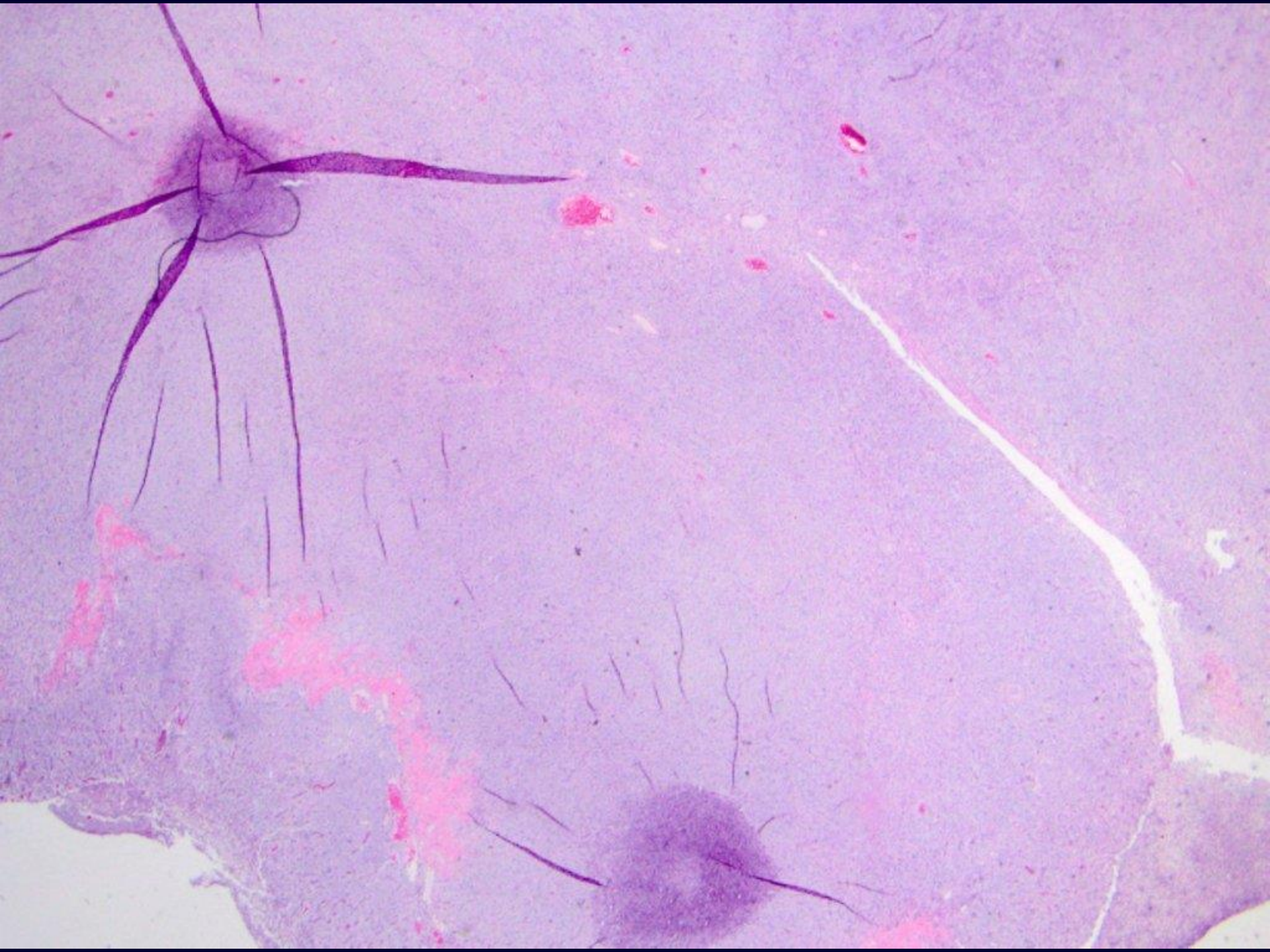


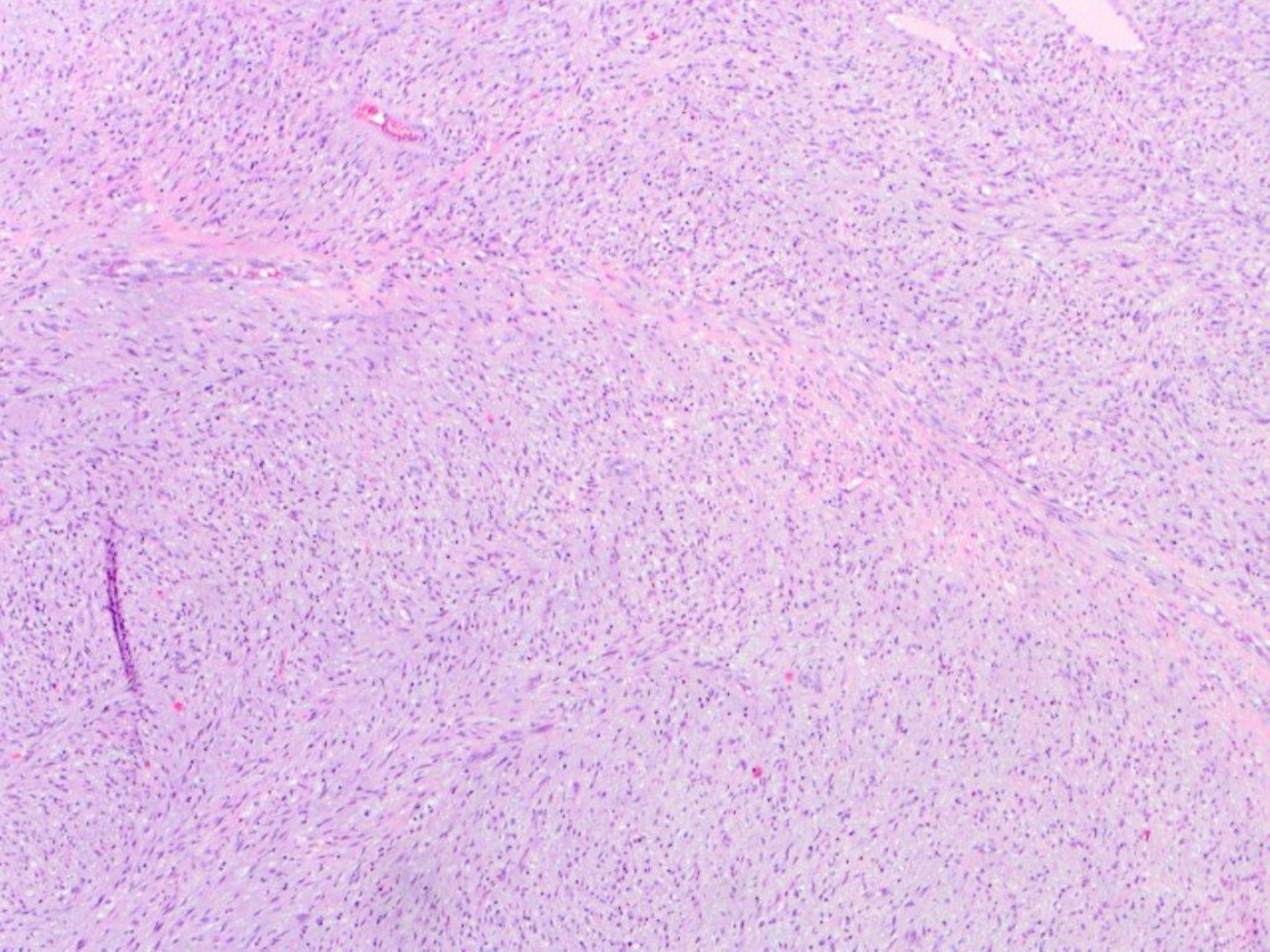


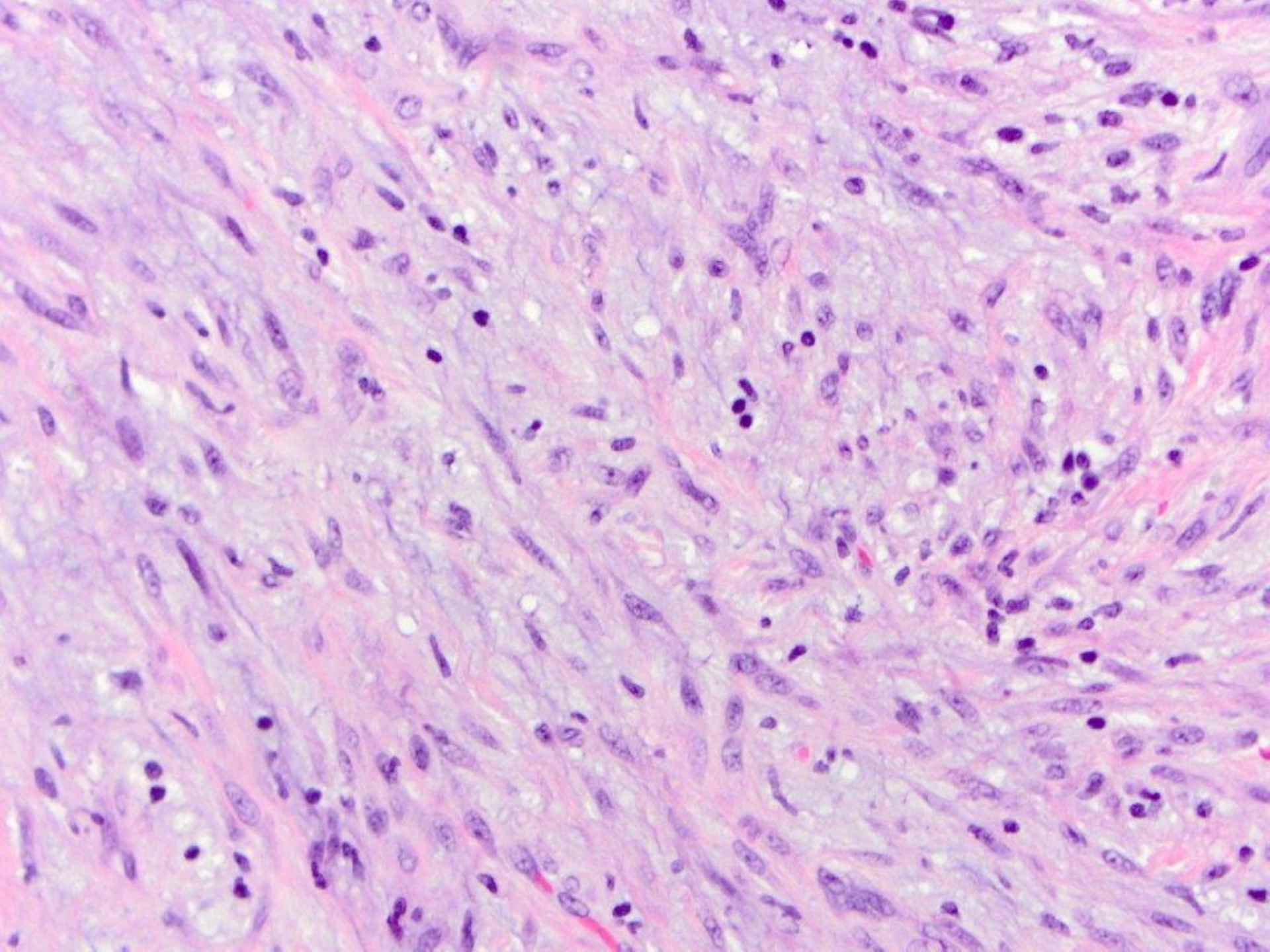


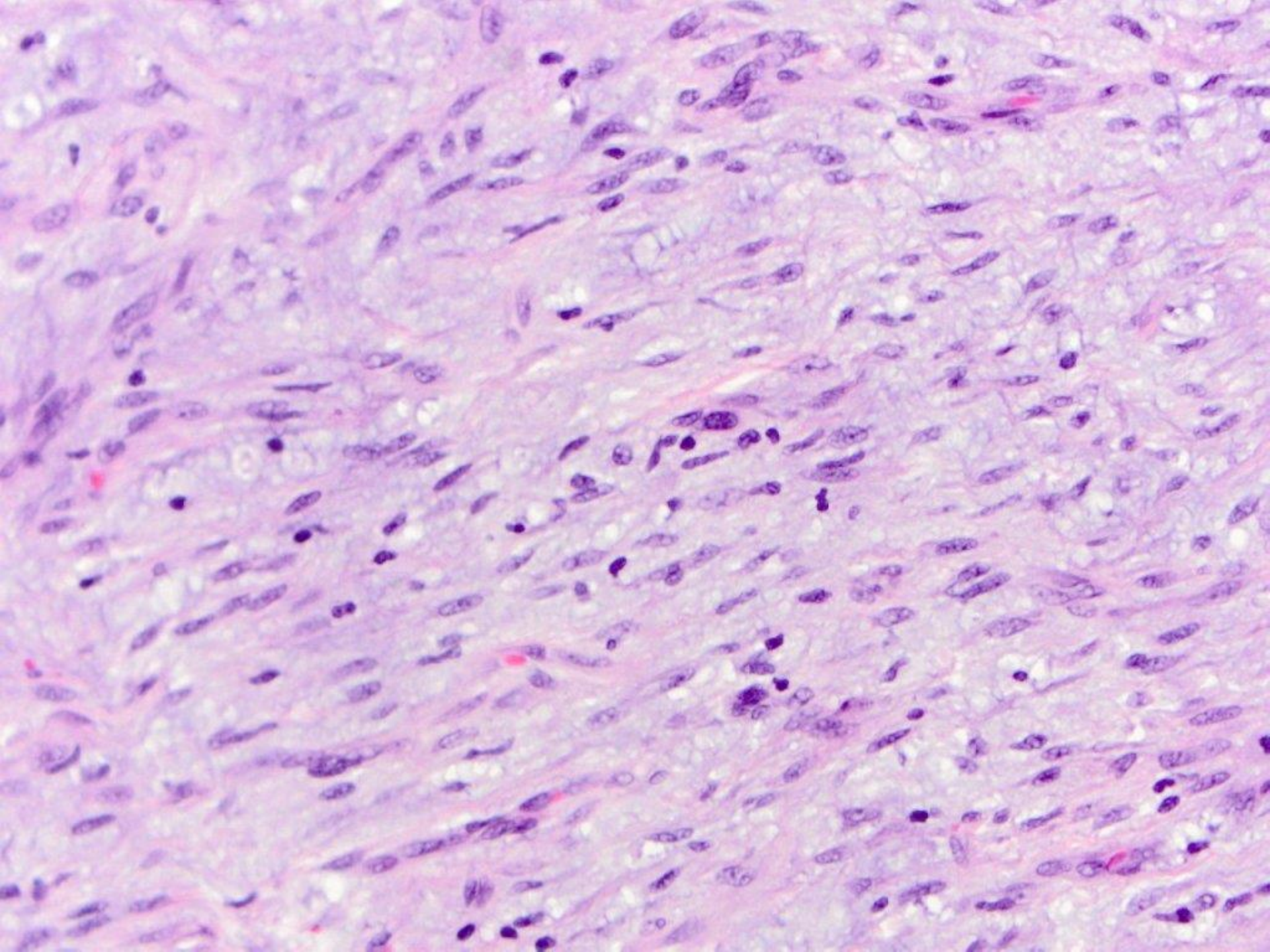


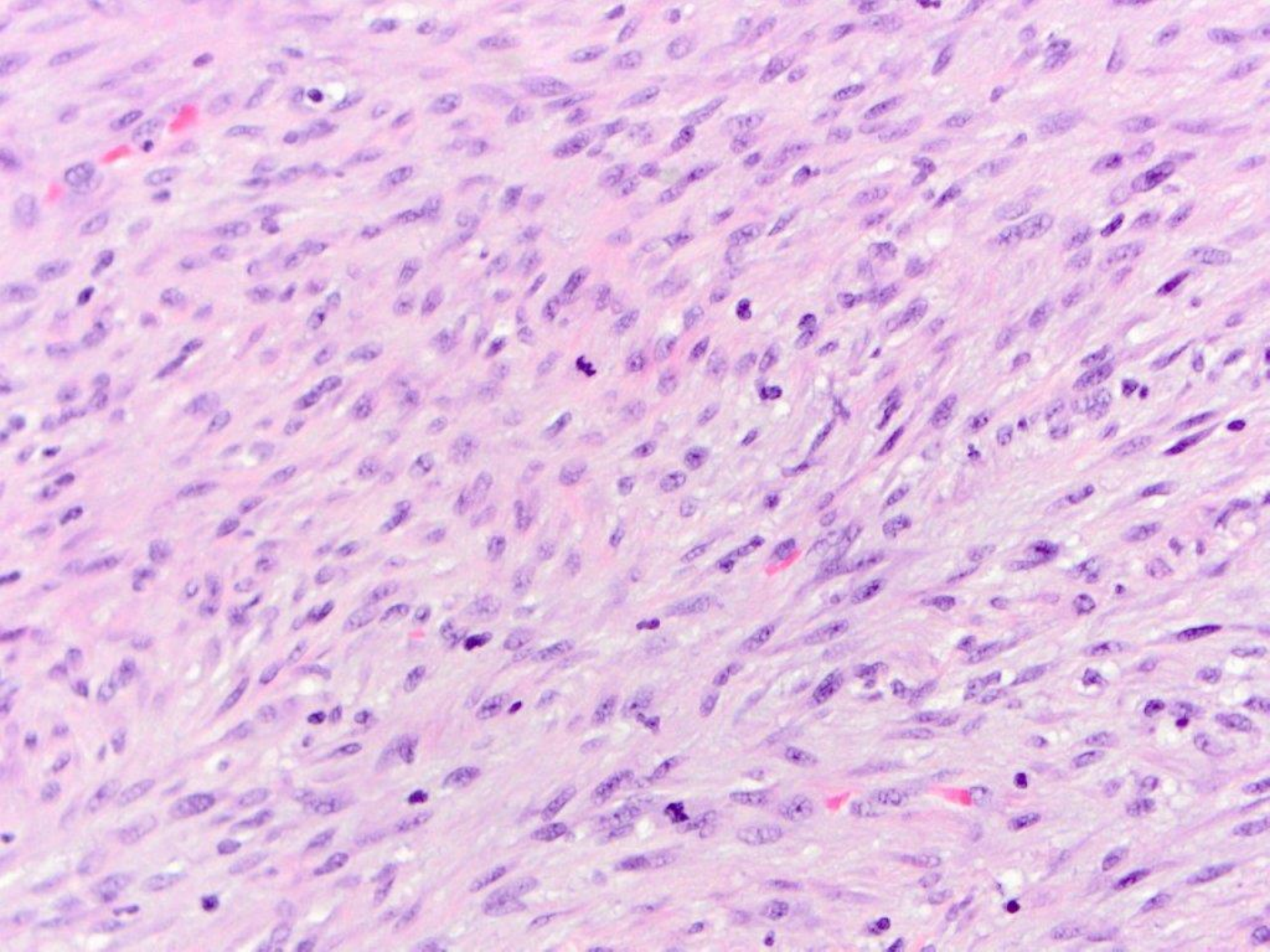
viral cytopathic effect, consistent with herpes simplex

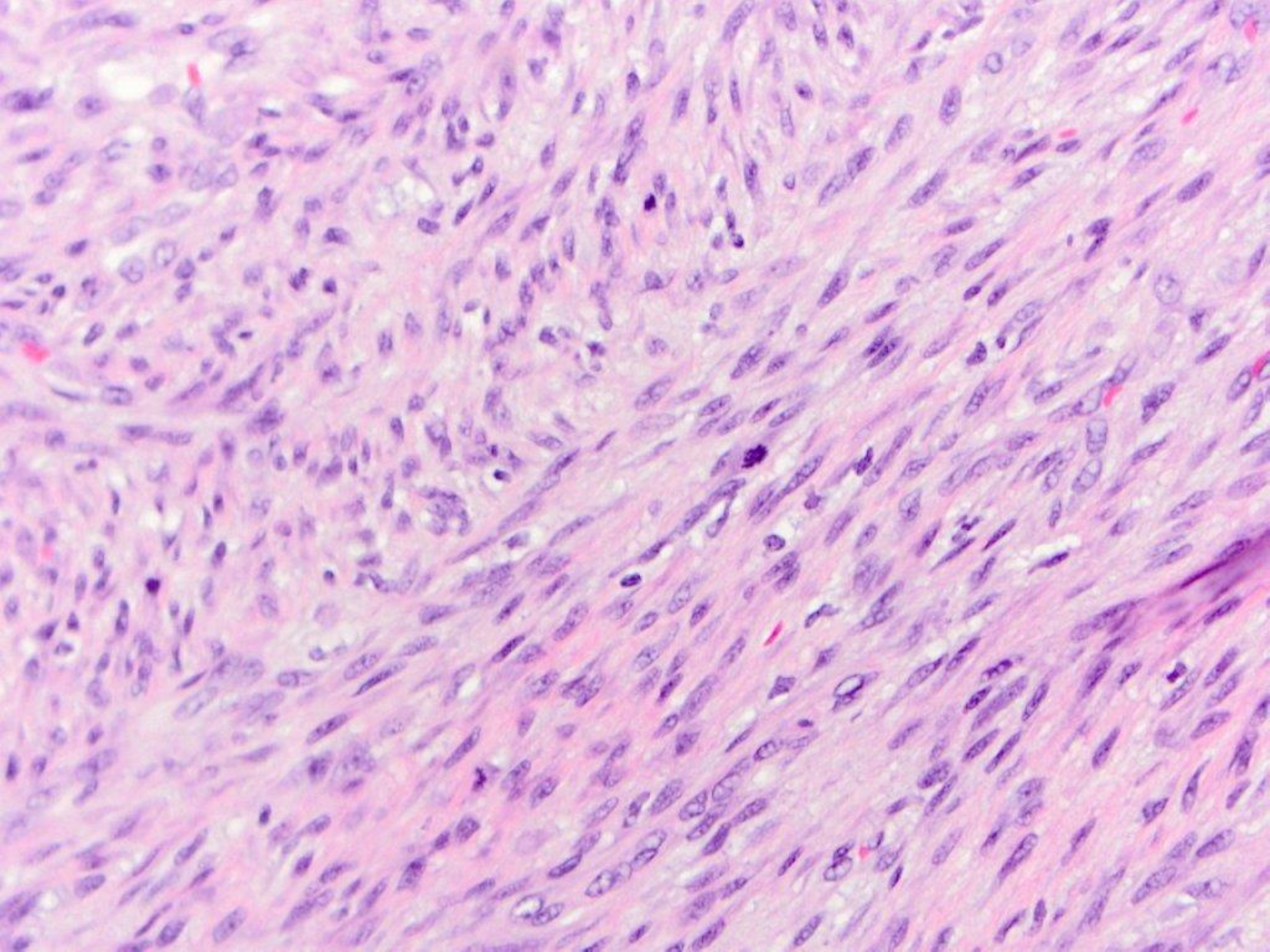


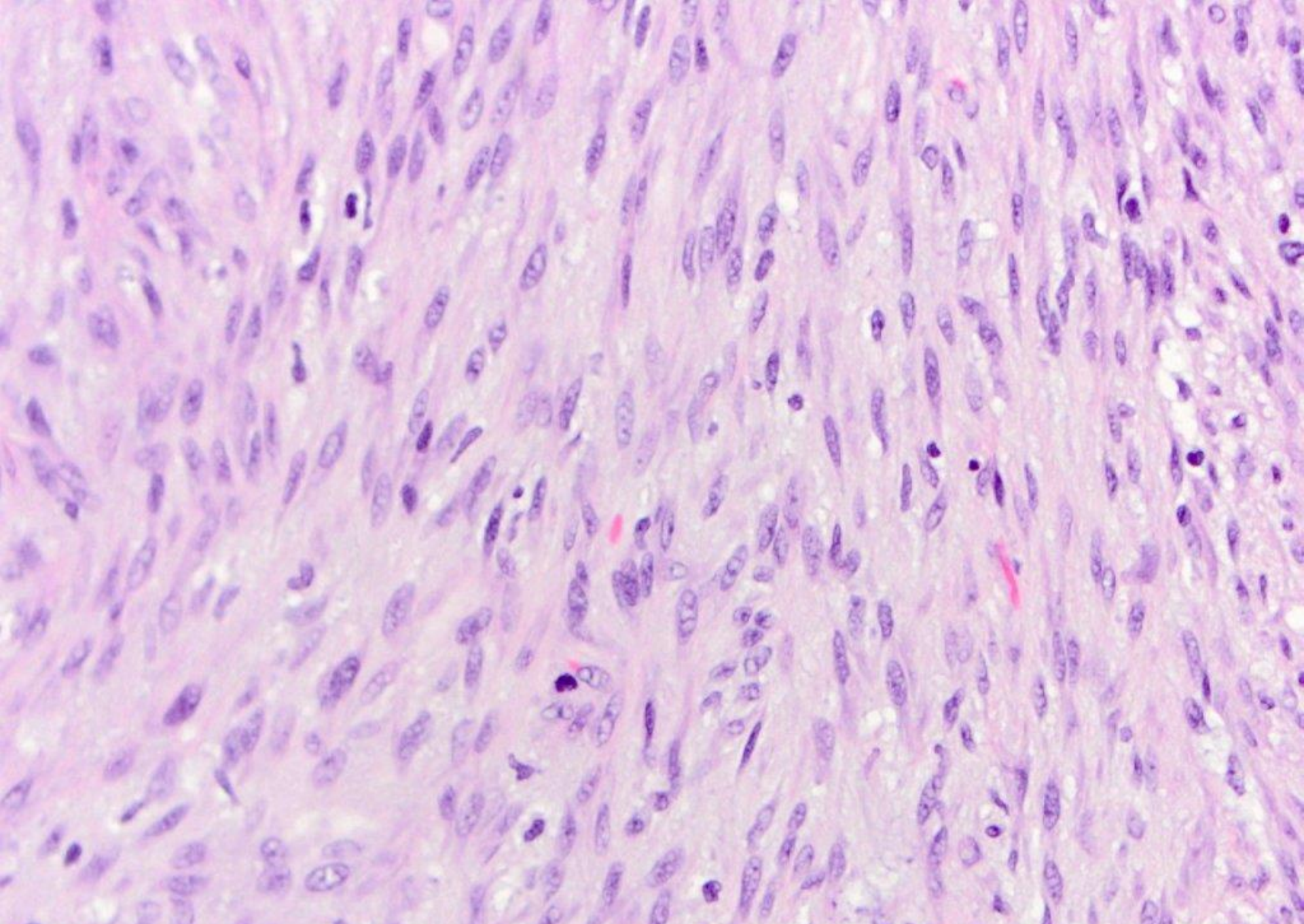




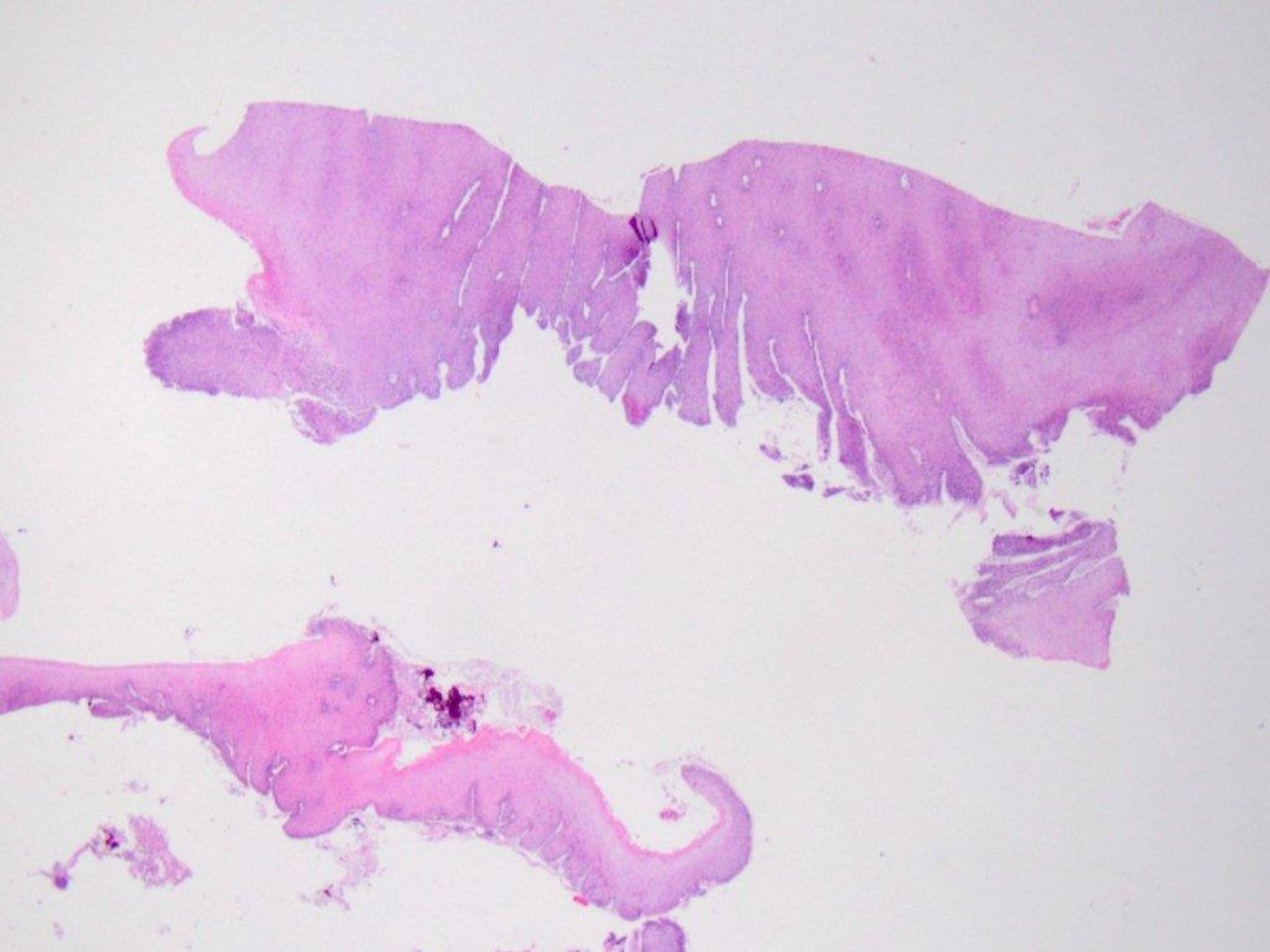

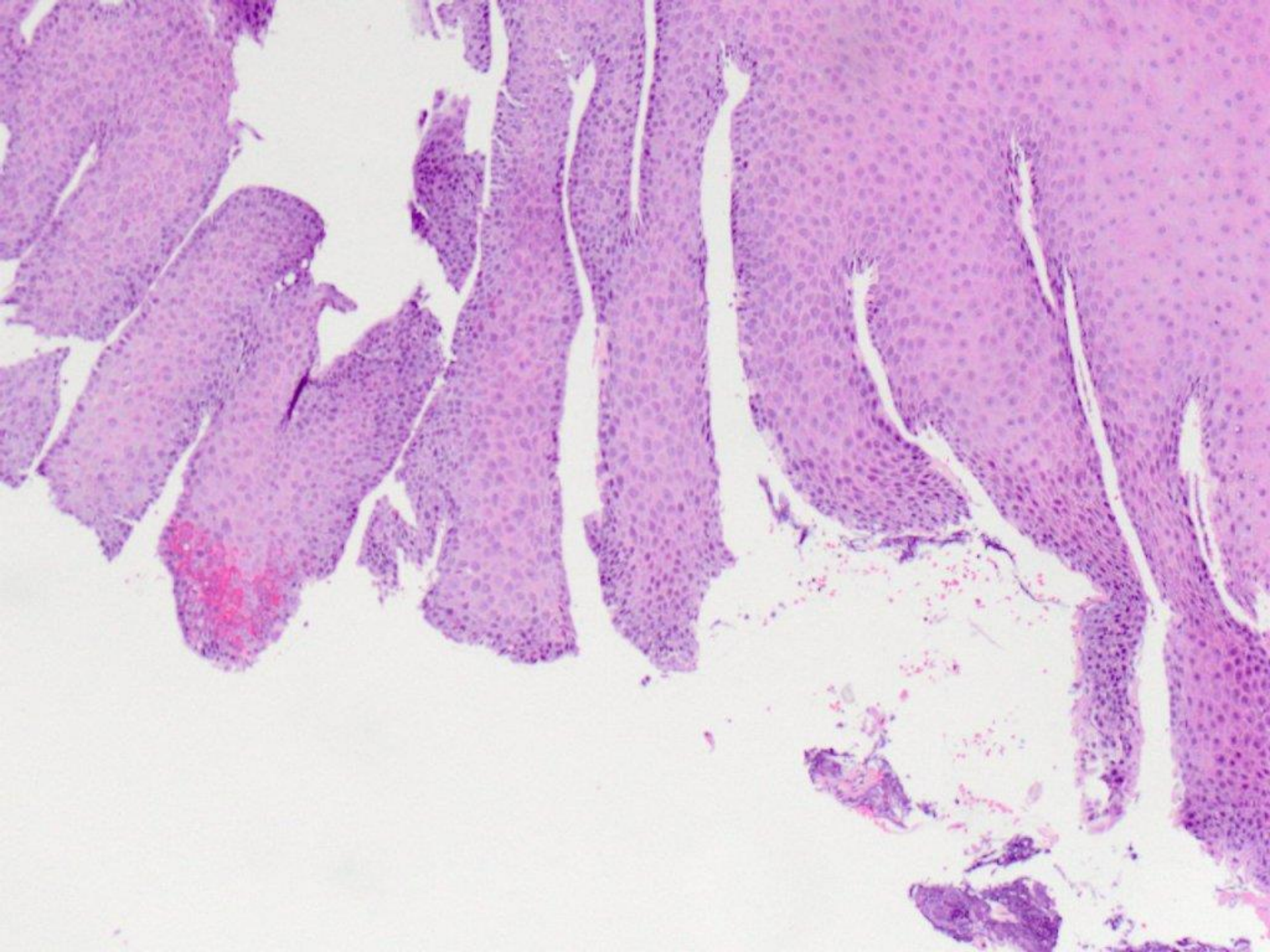


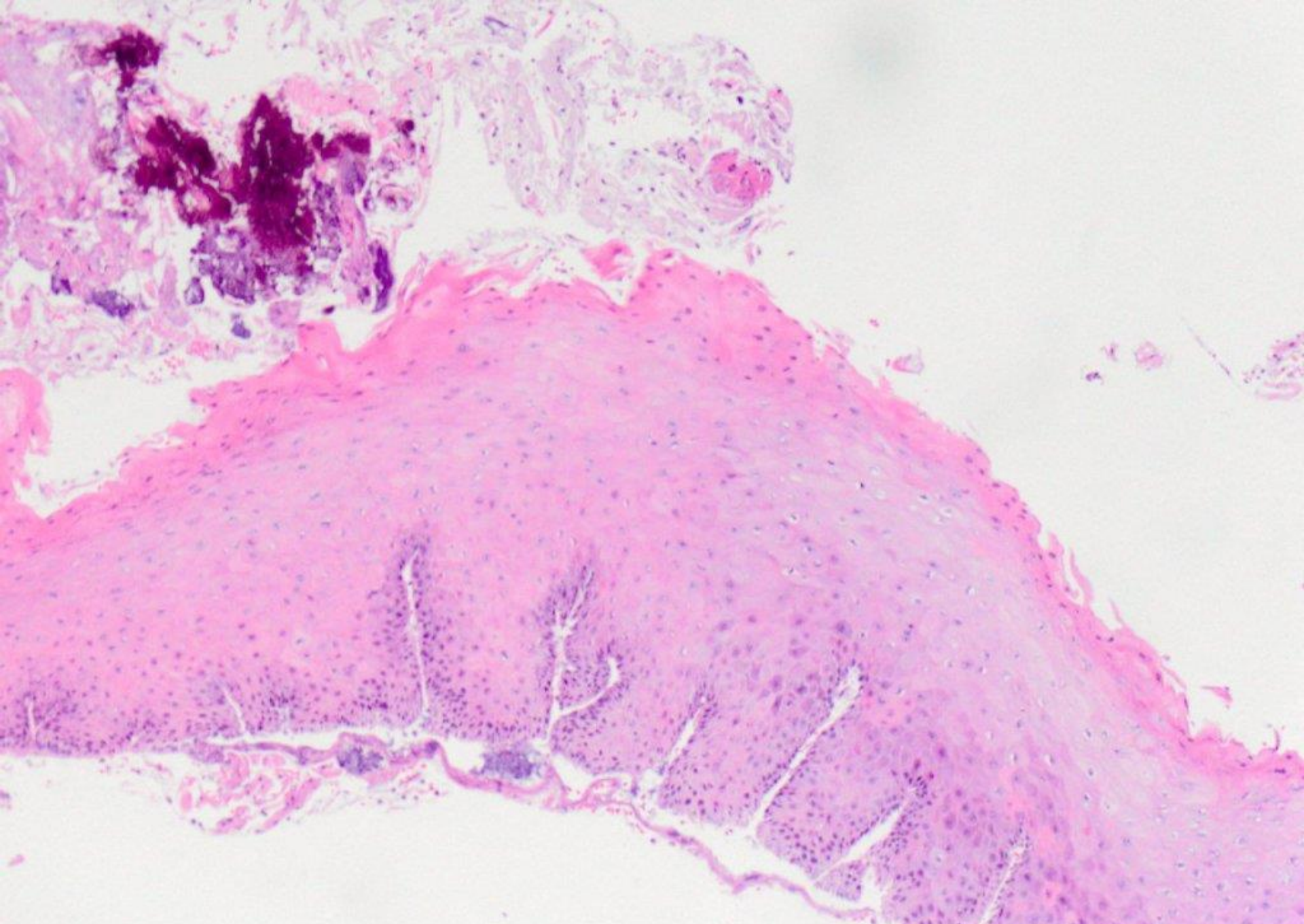




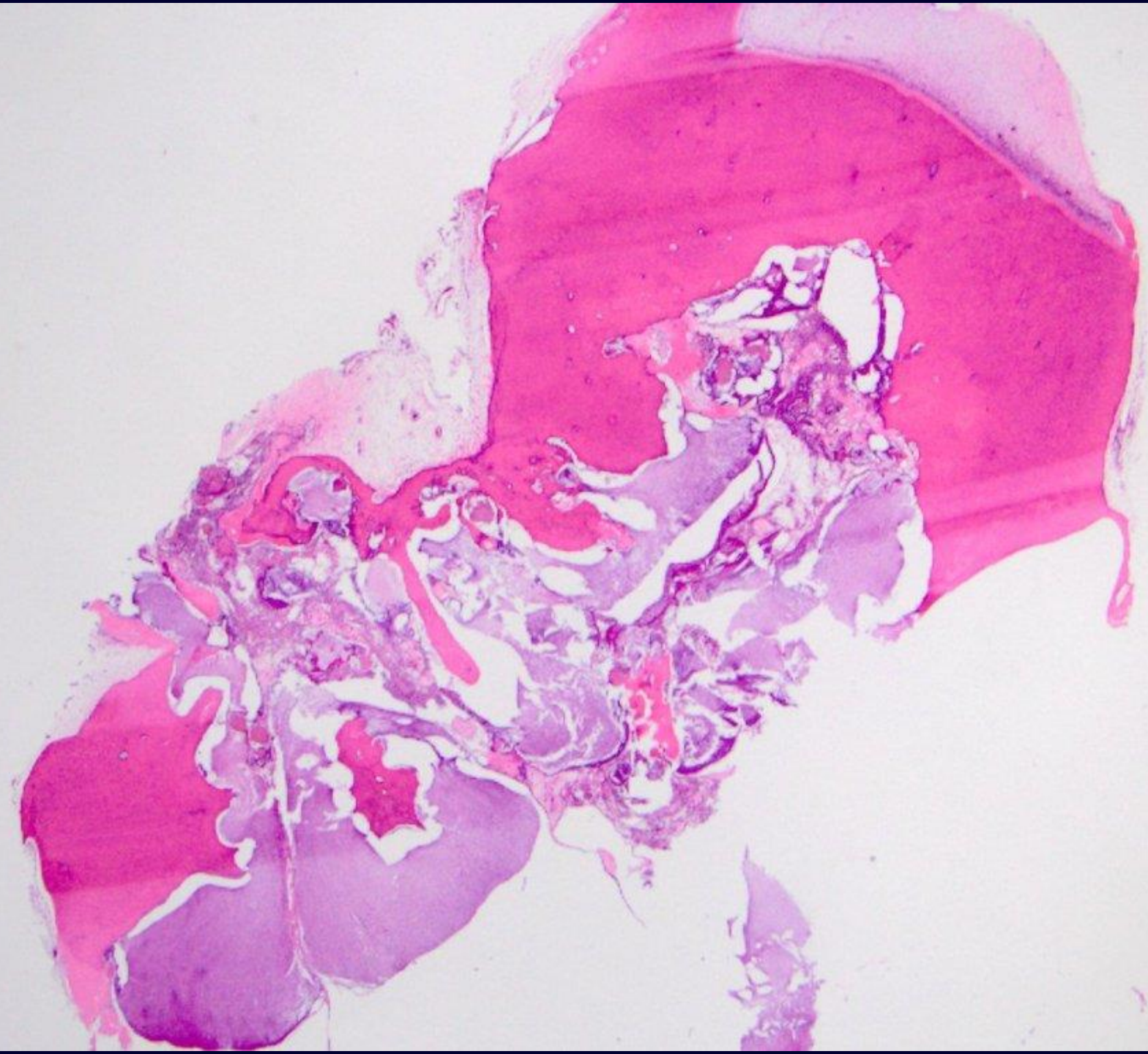
myofibroma (myofibromatosis)

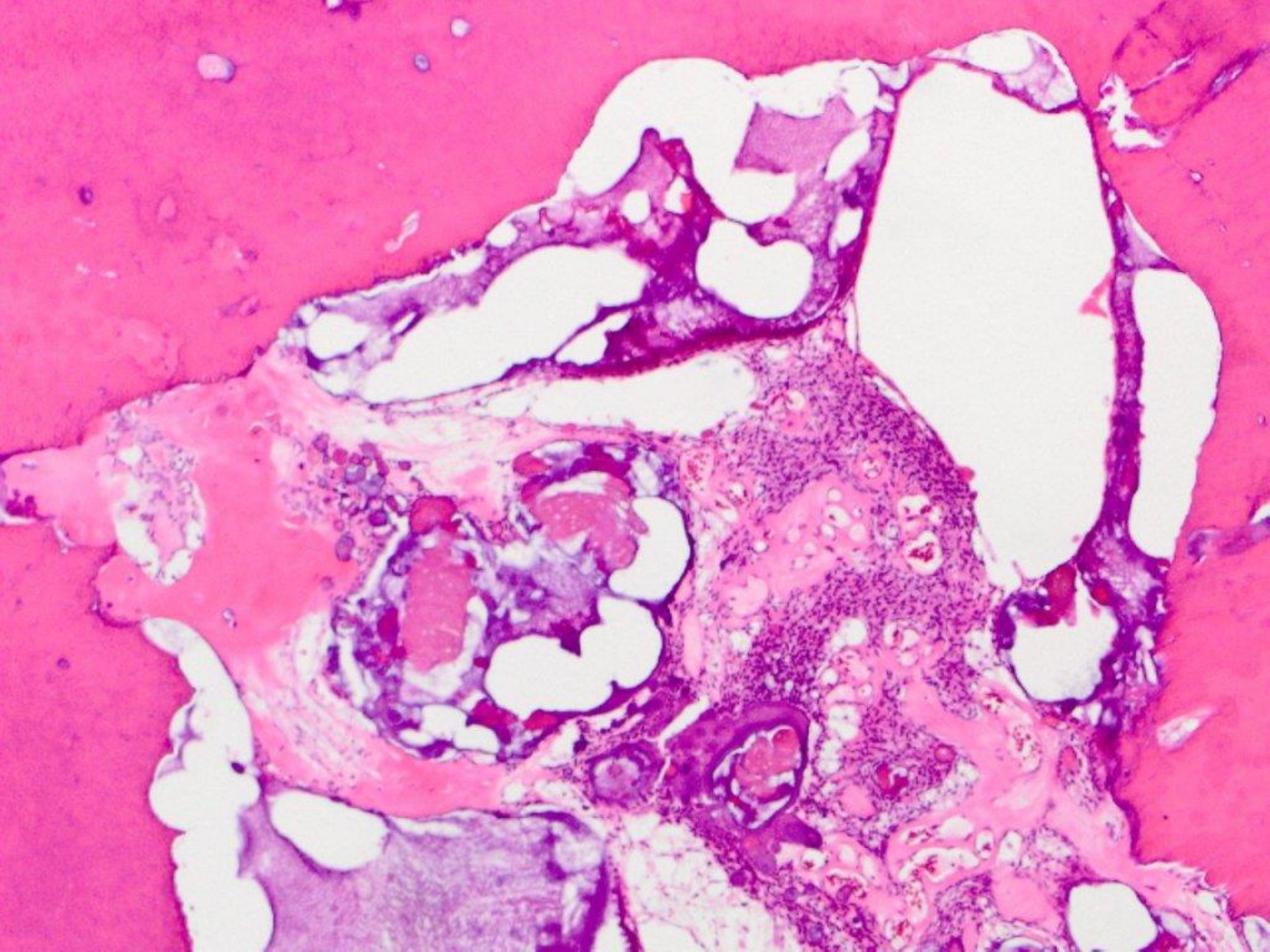


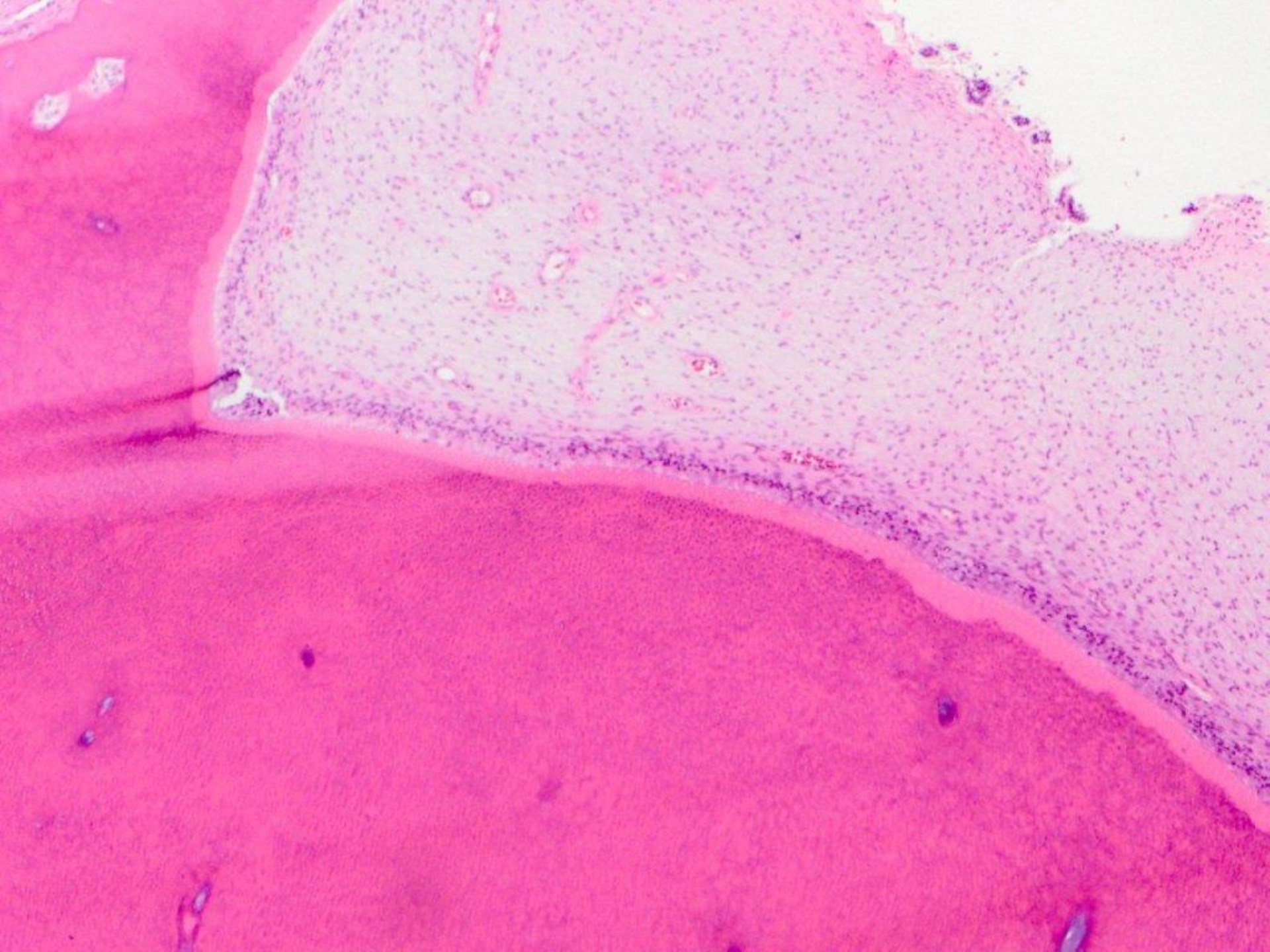


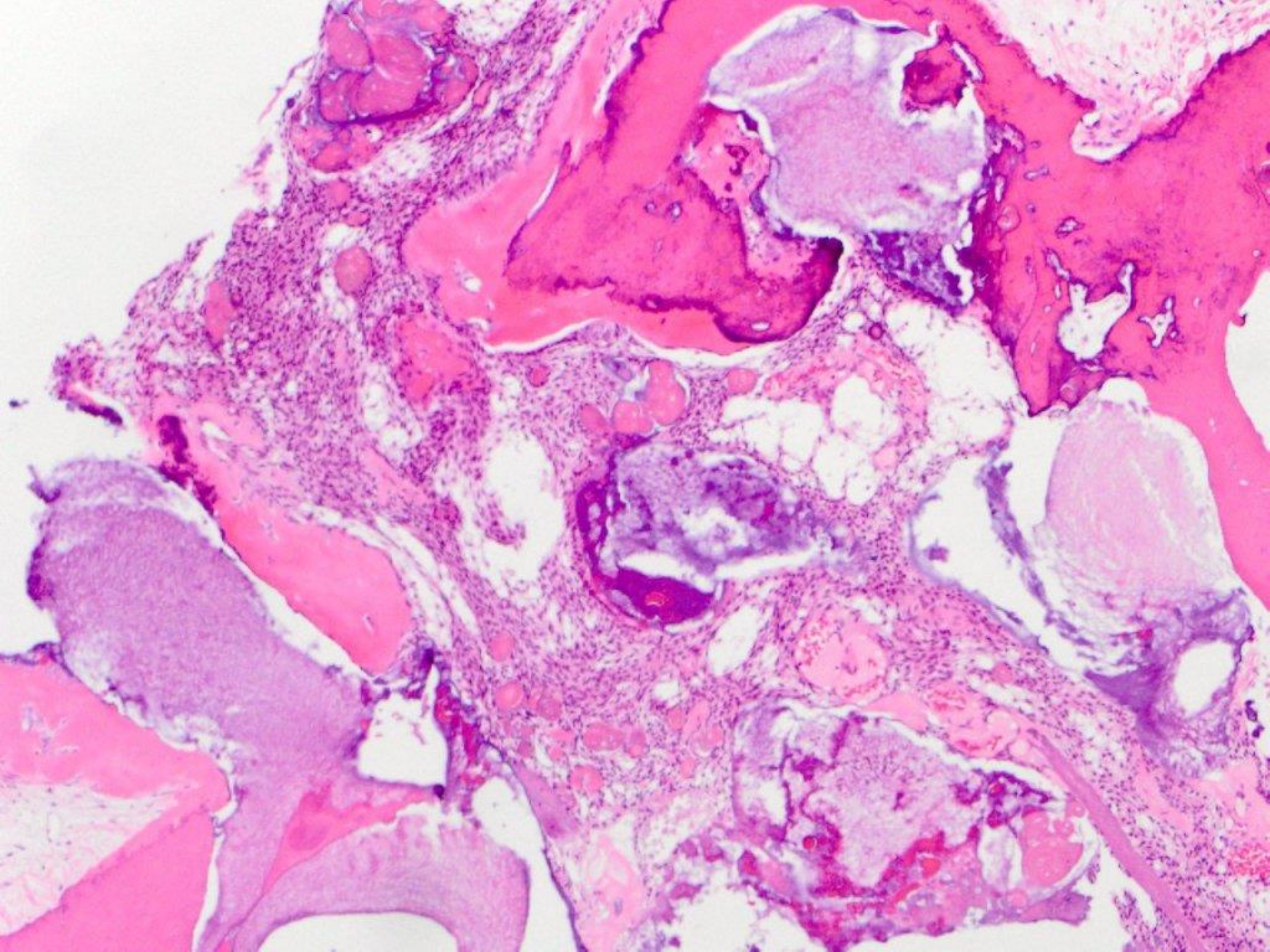


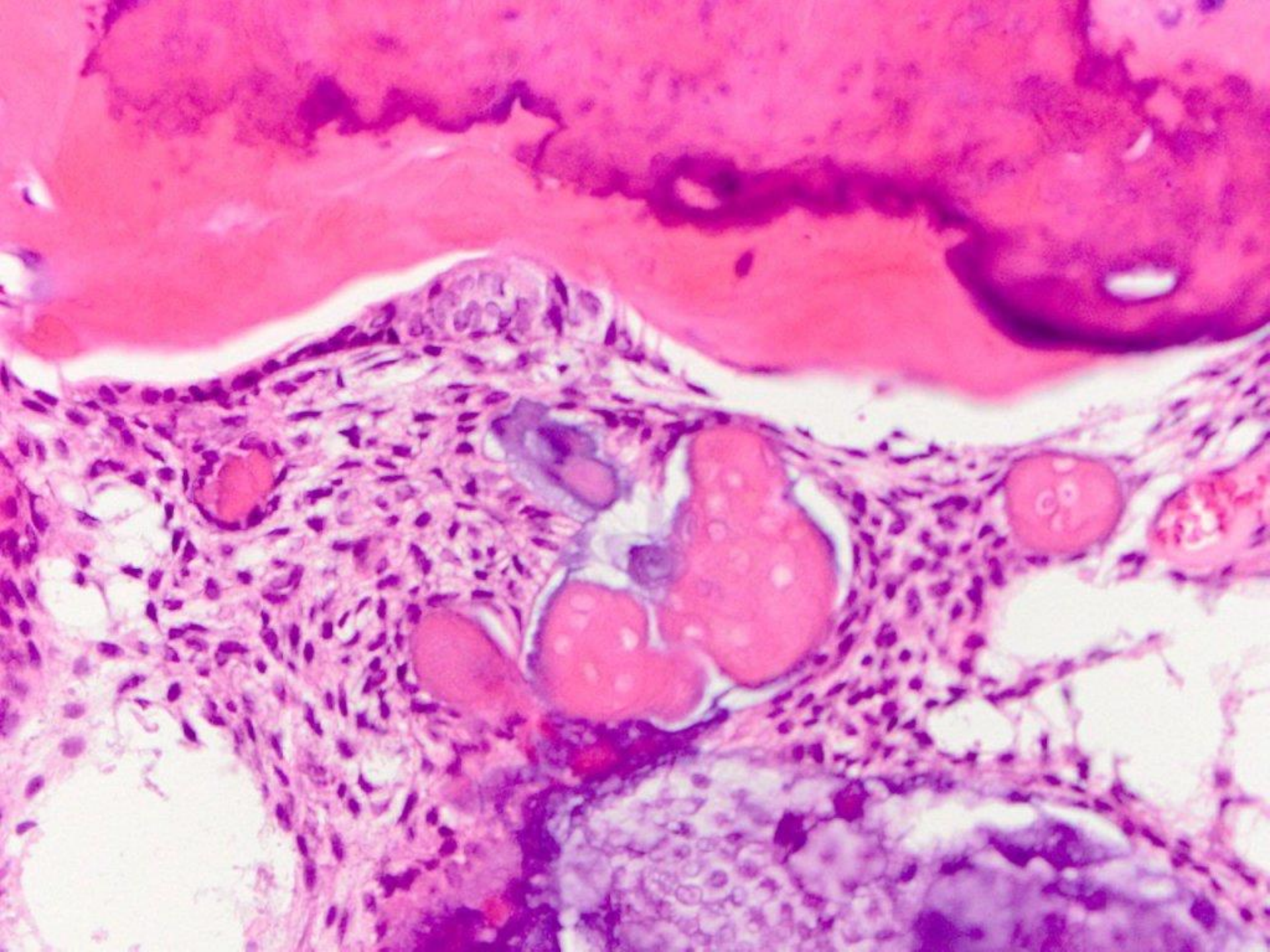
pemphigoid

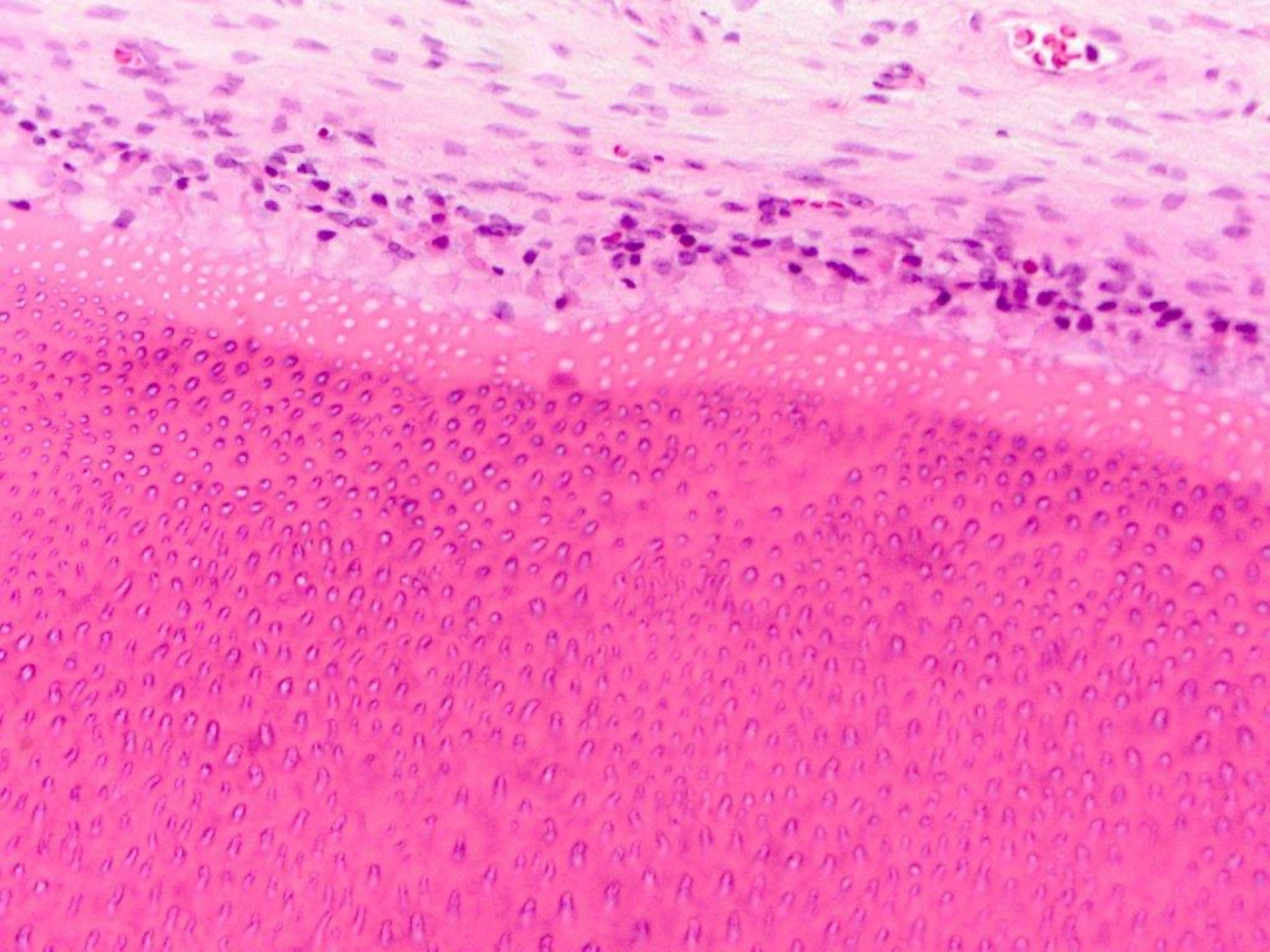


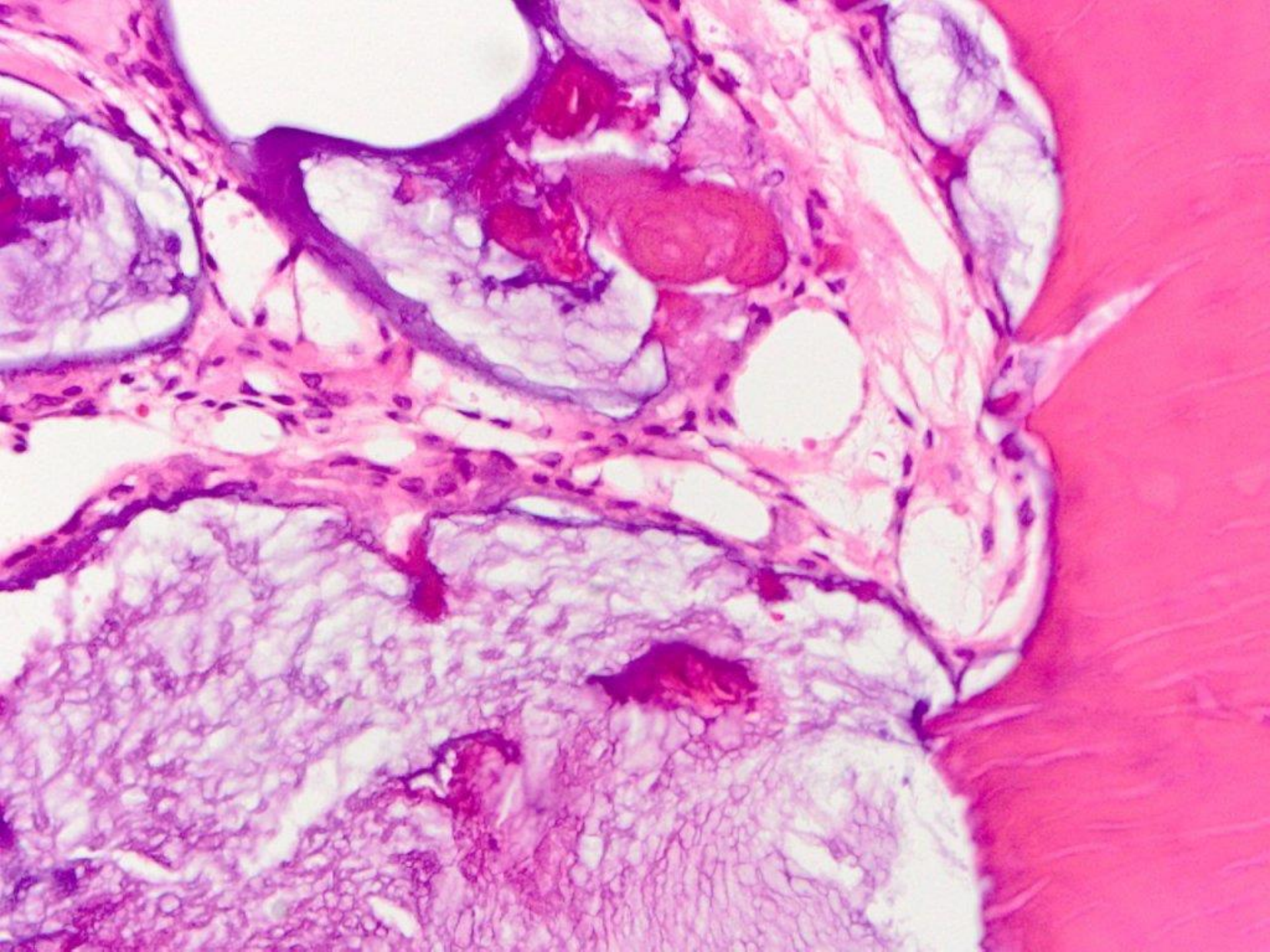


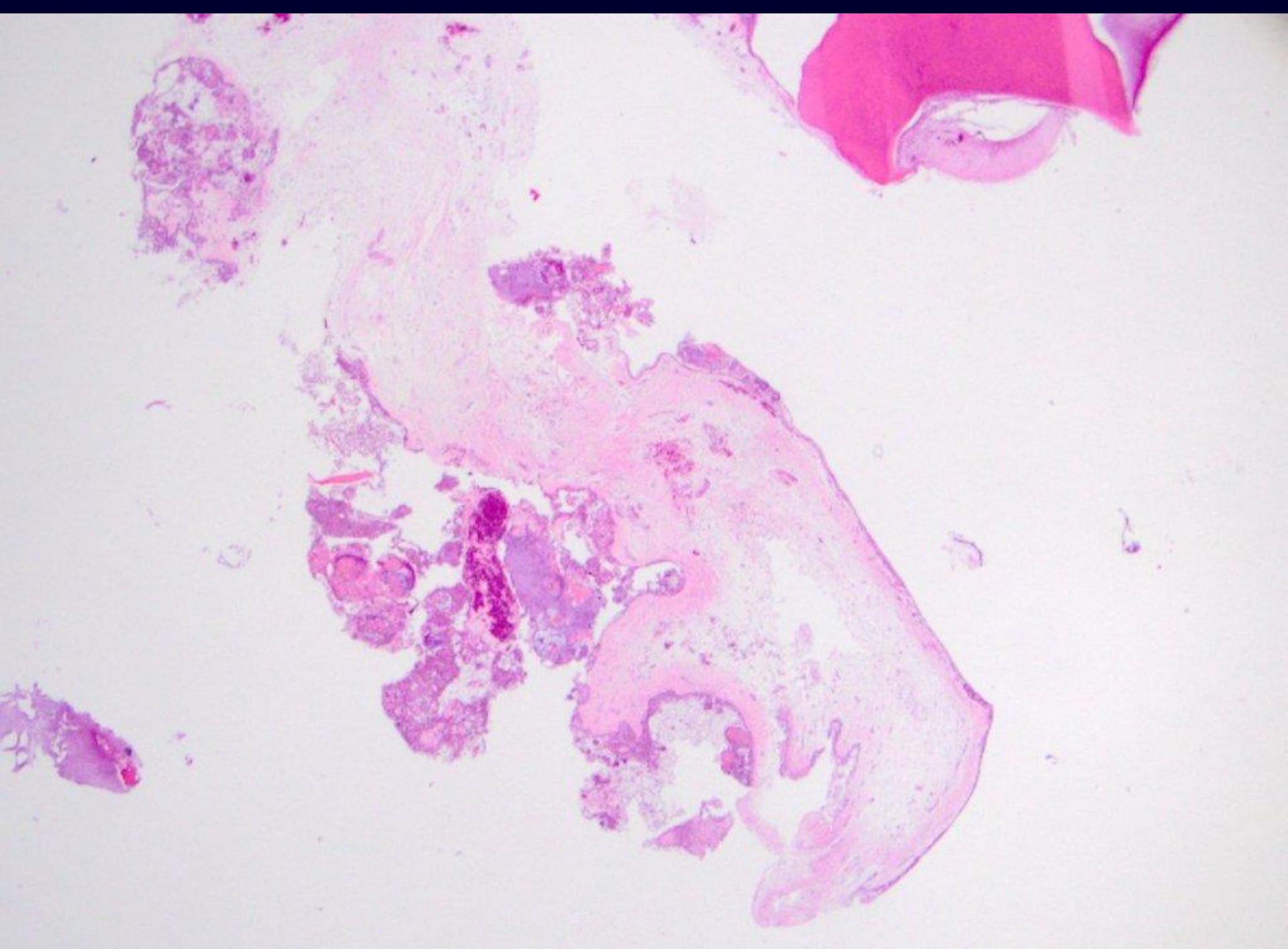


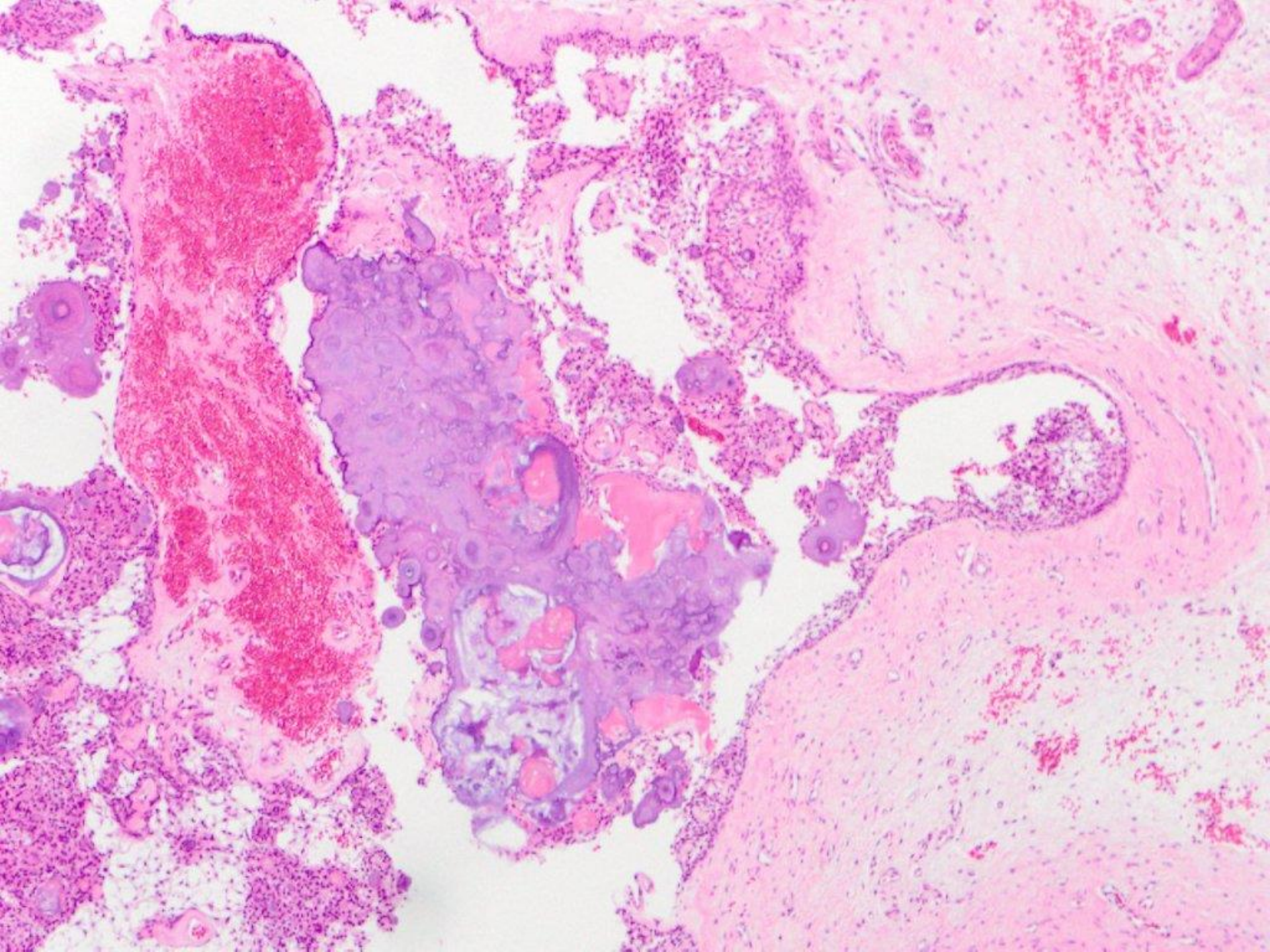


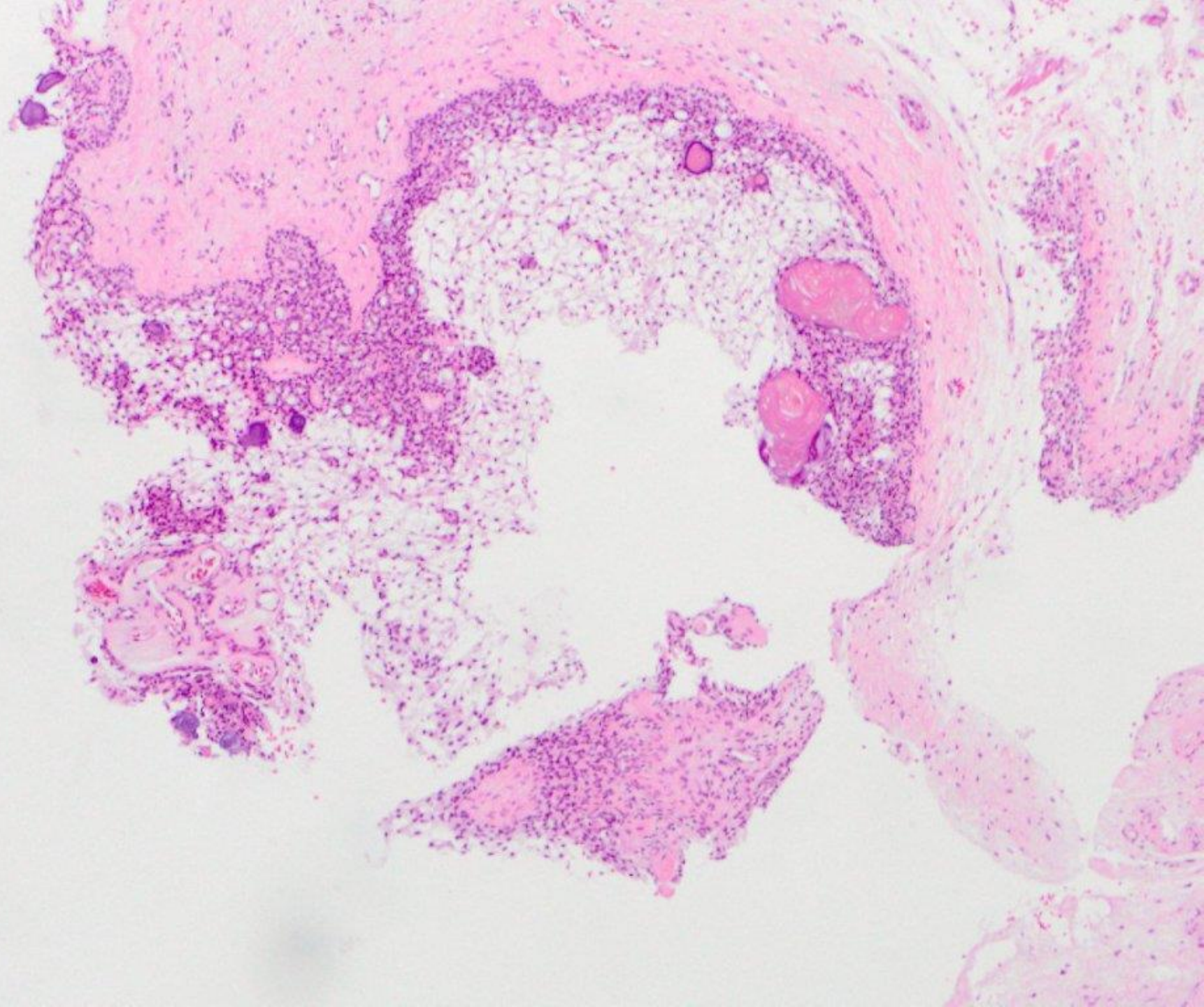


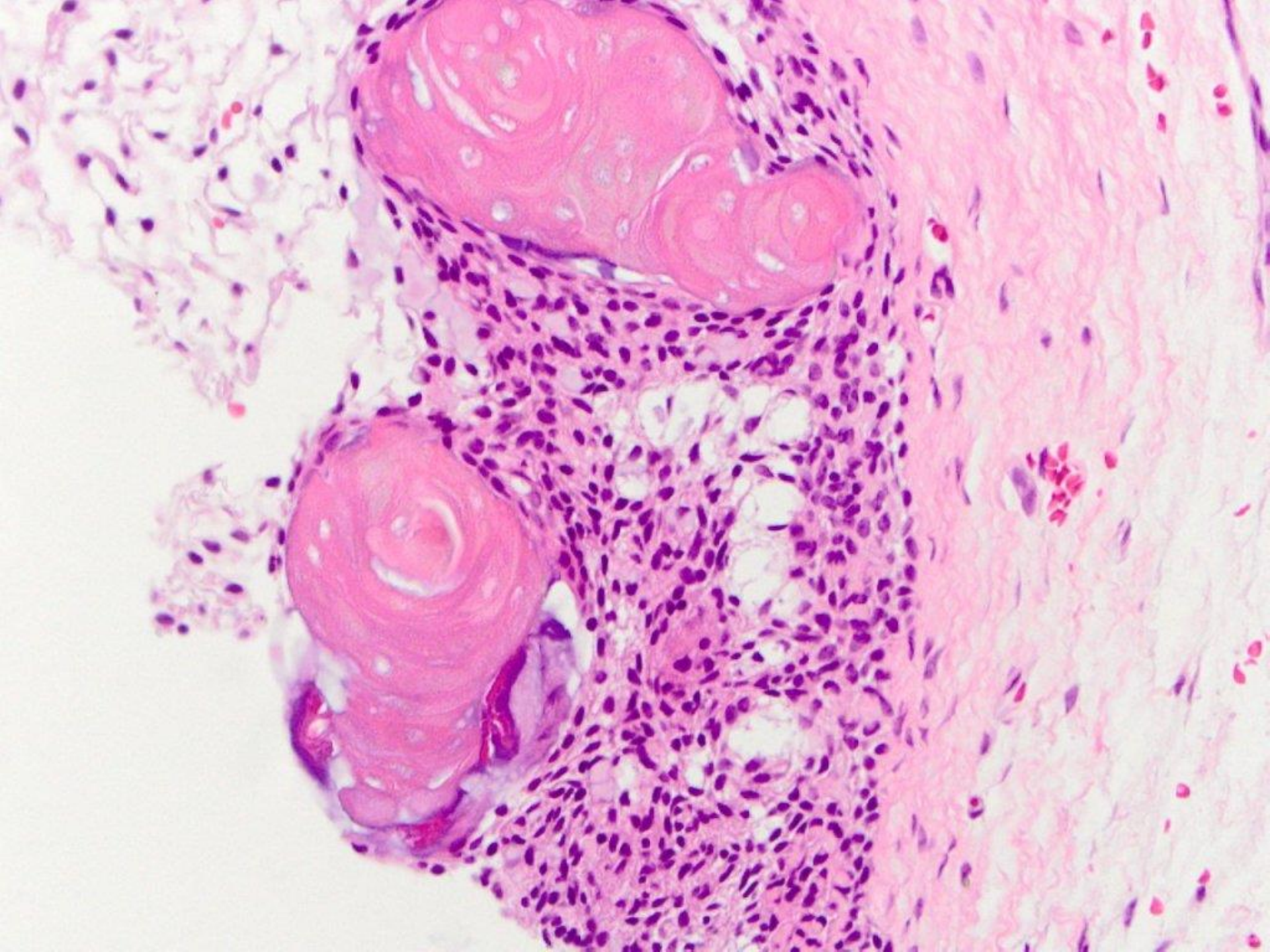


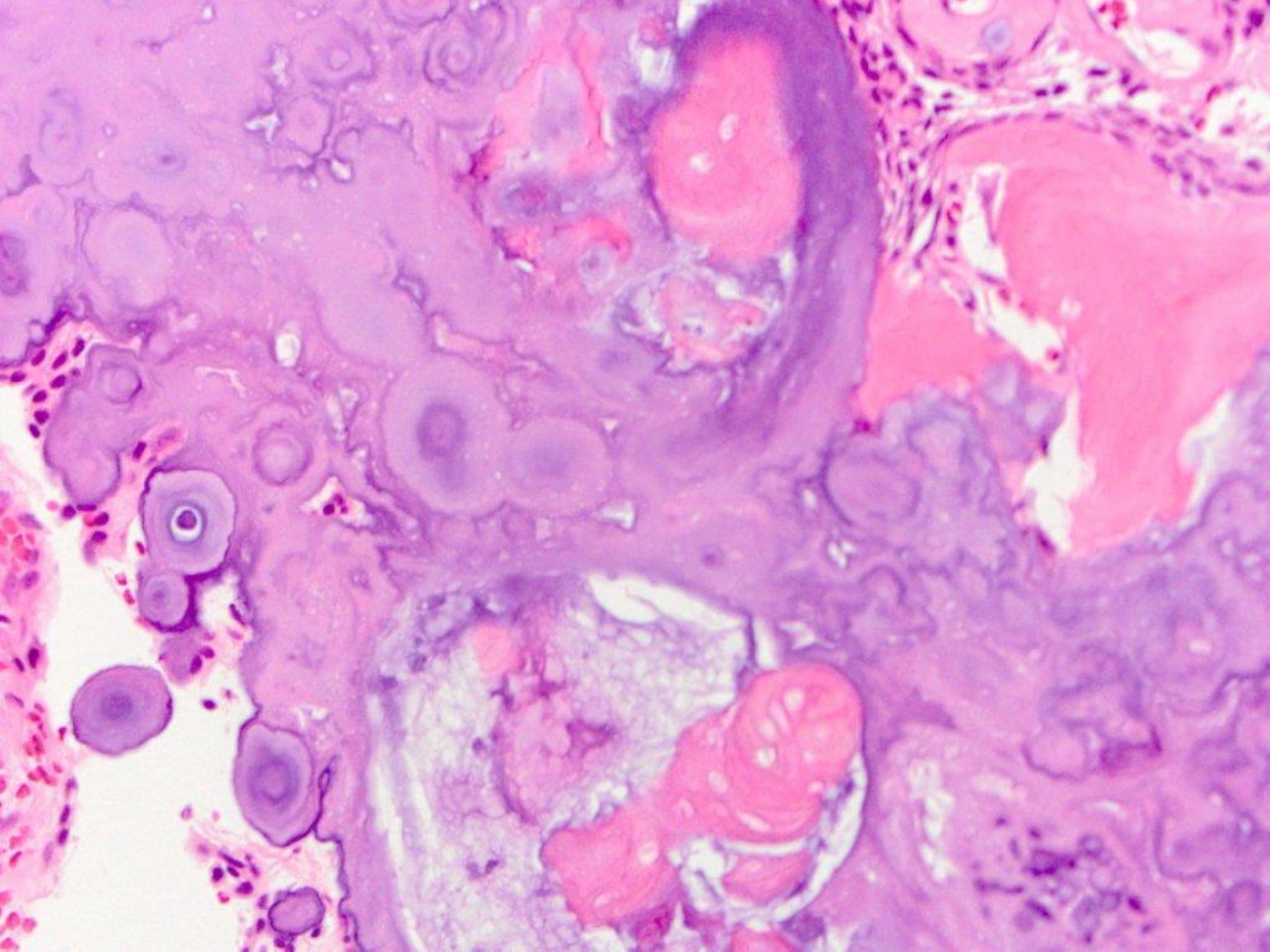


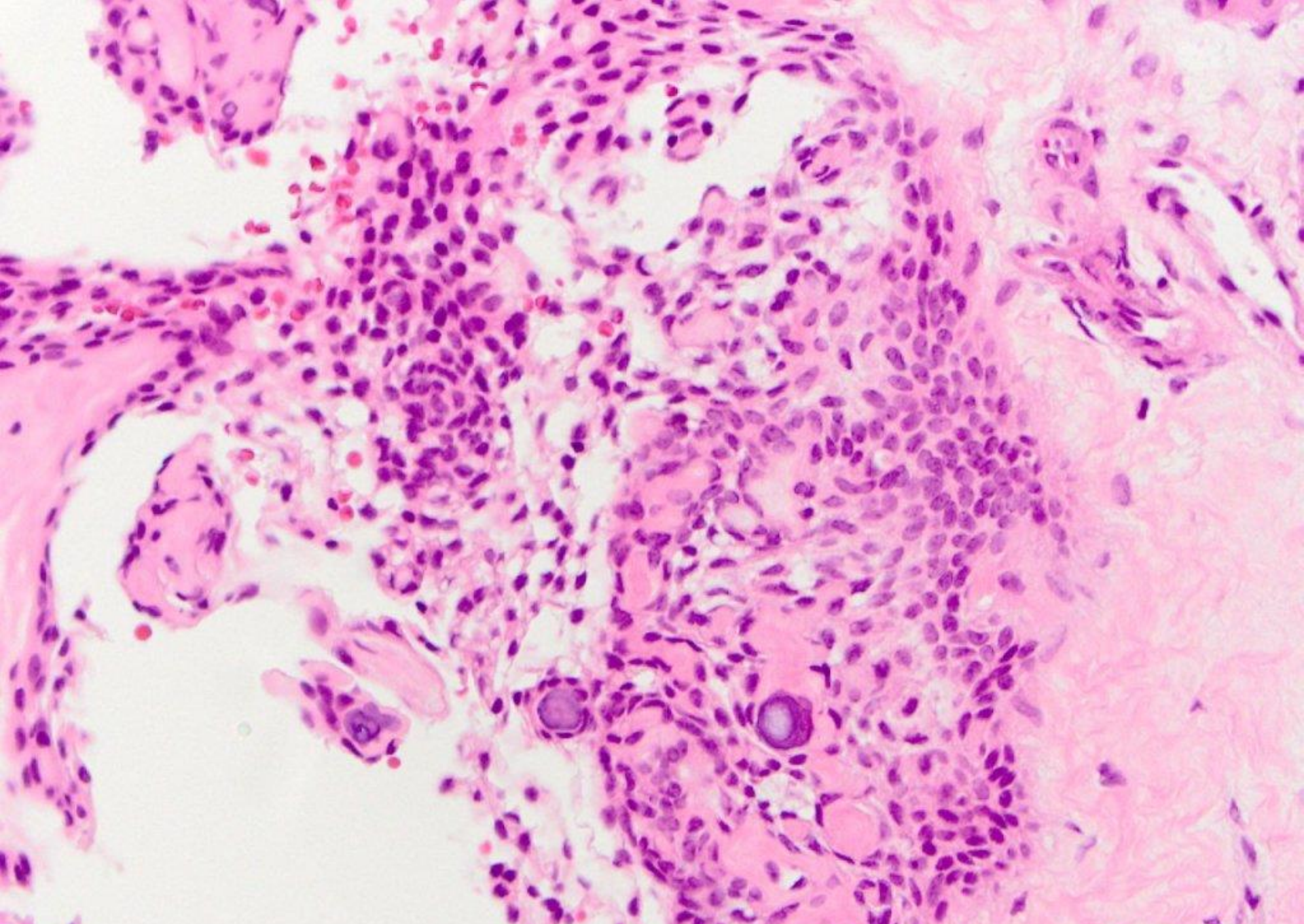




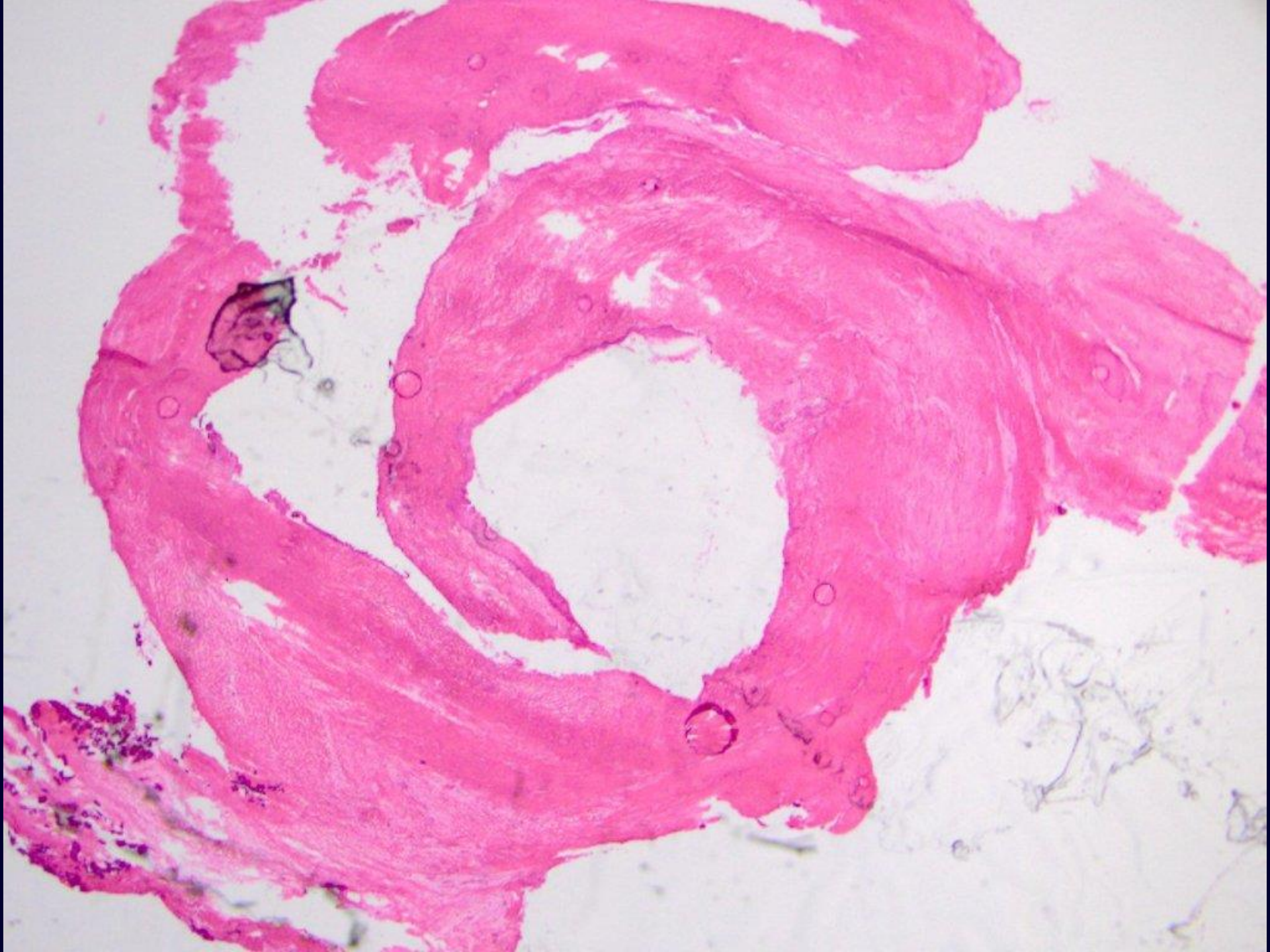

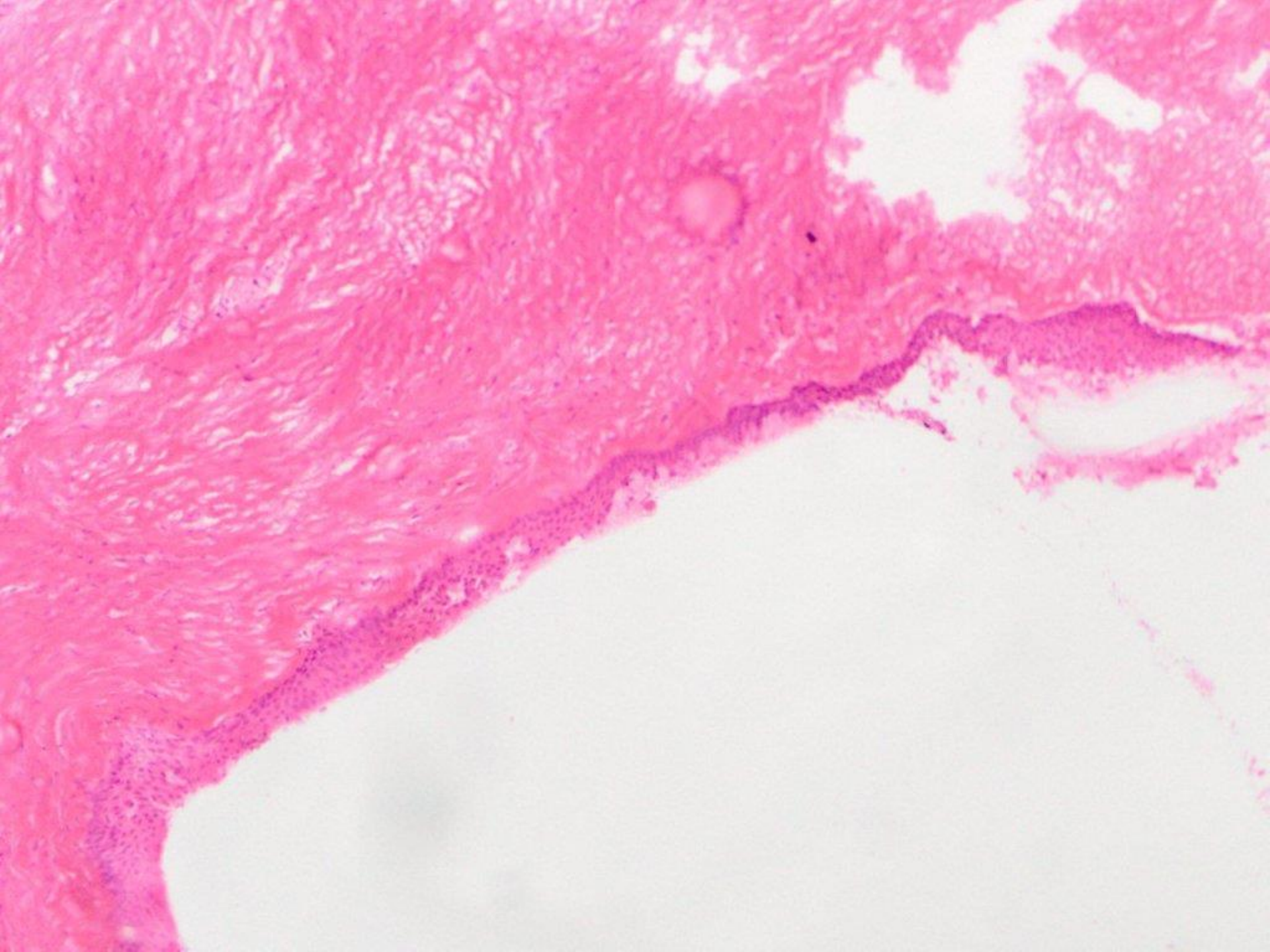


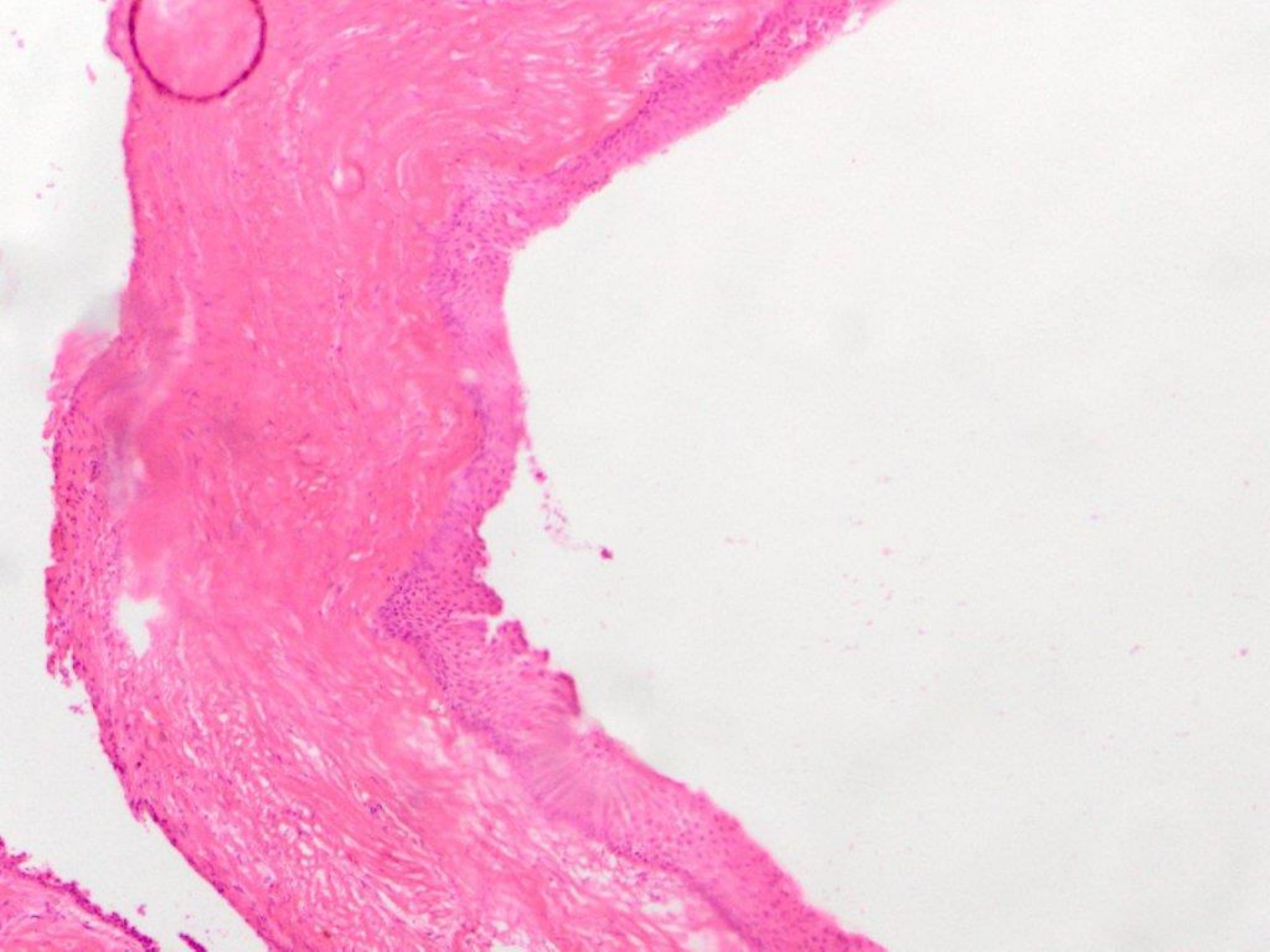


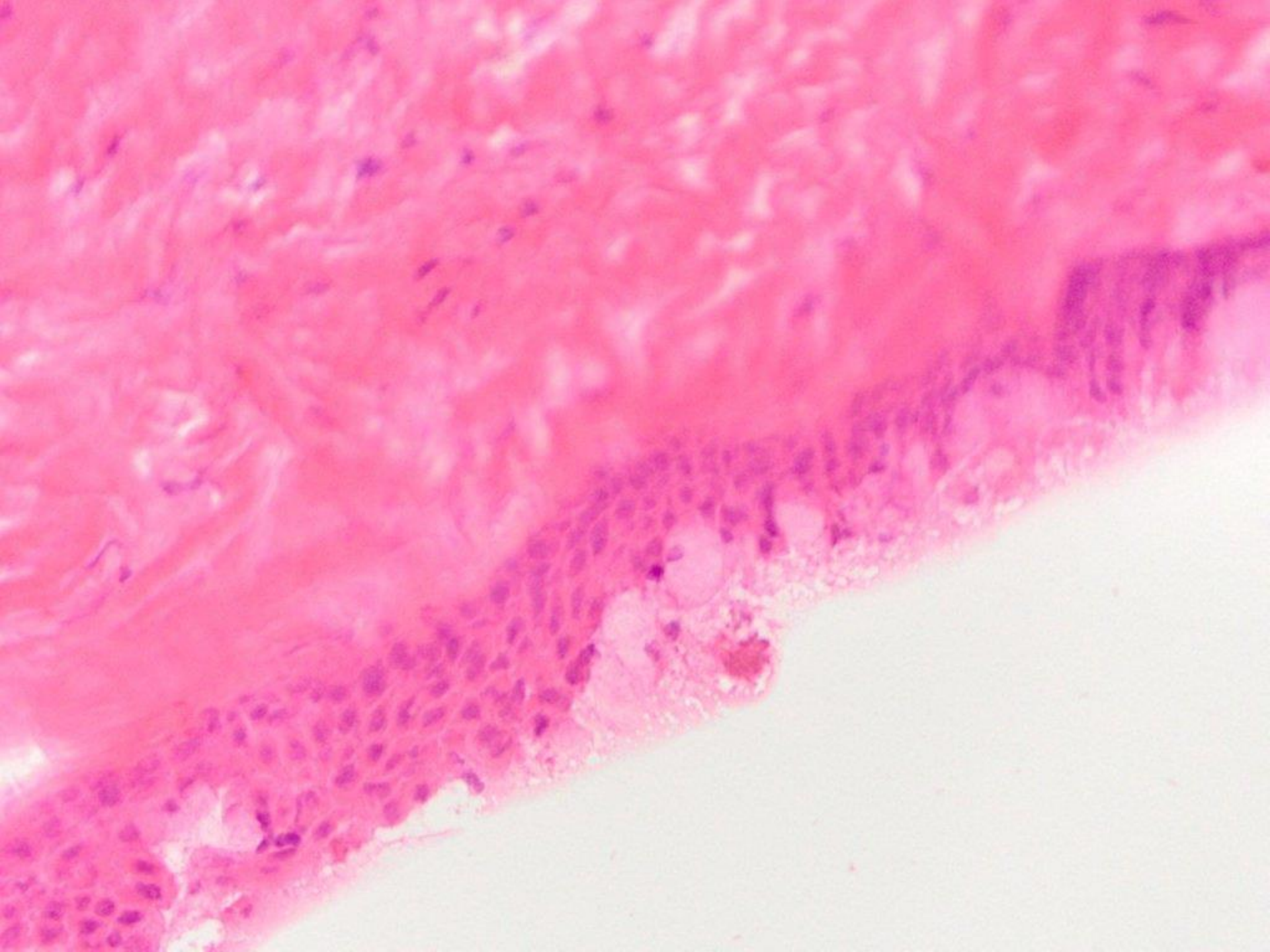


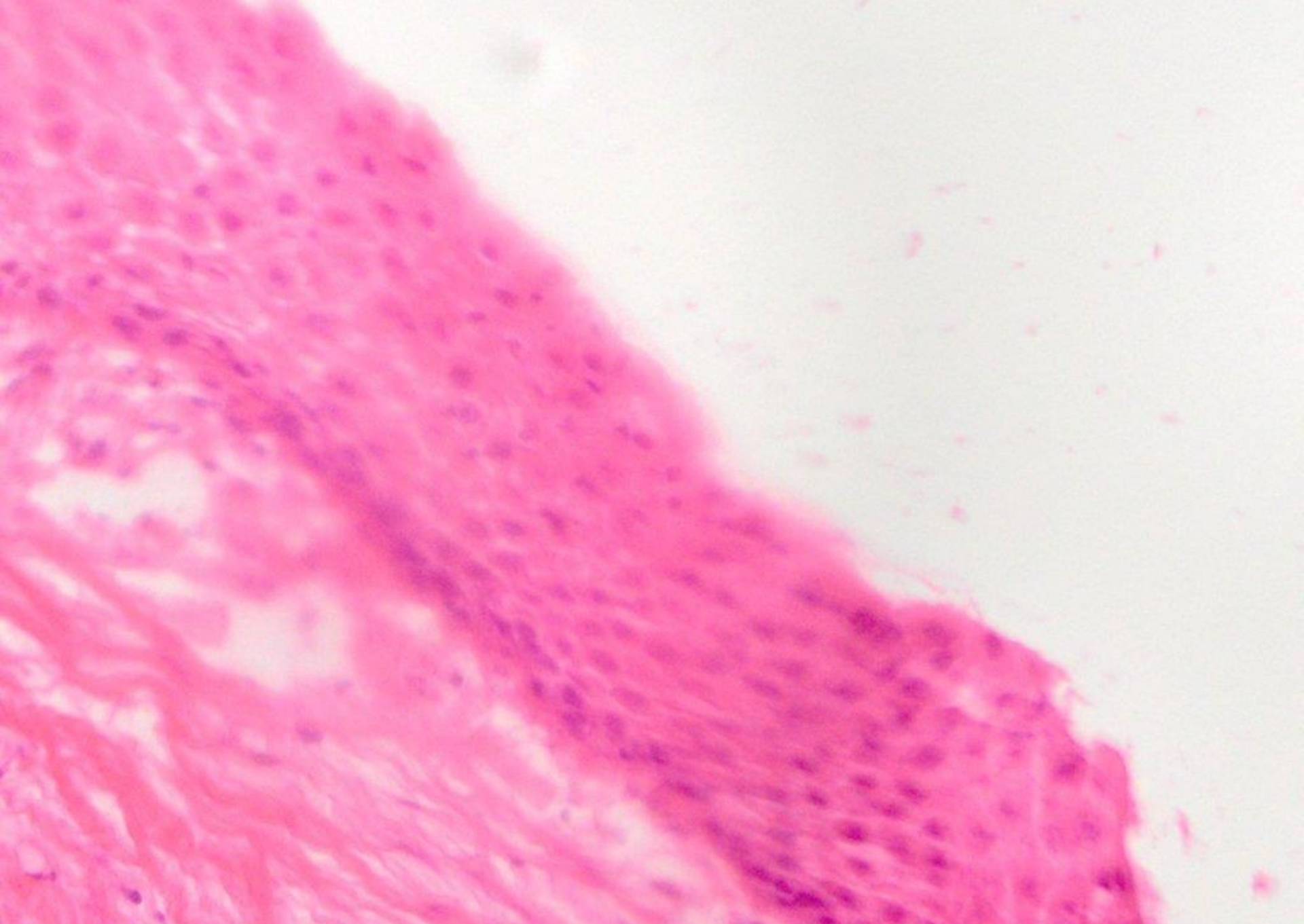
(complex) odontoma and calcifying (ghost cell) odontogenic cyst



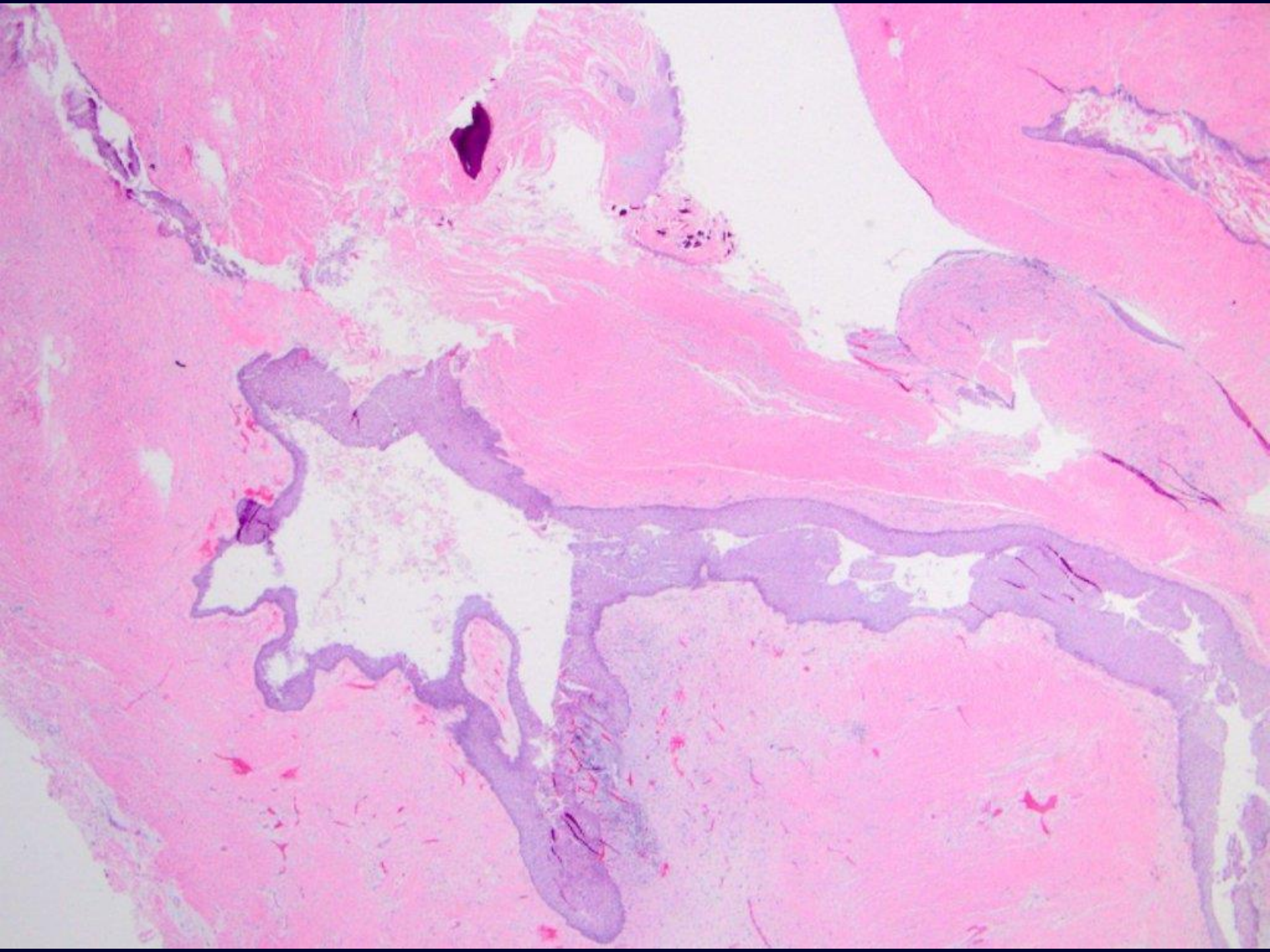


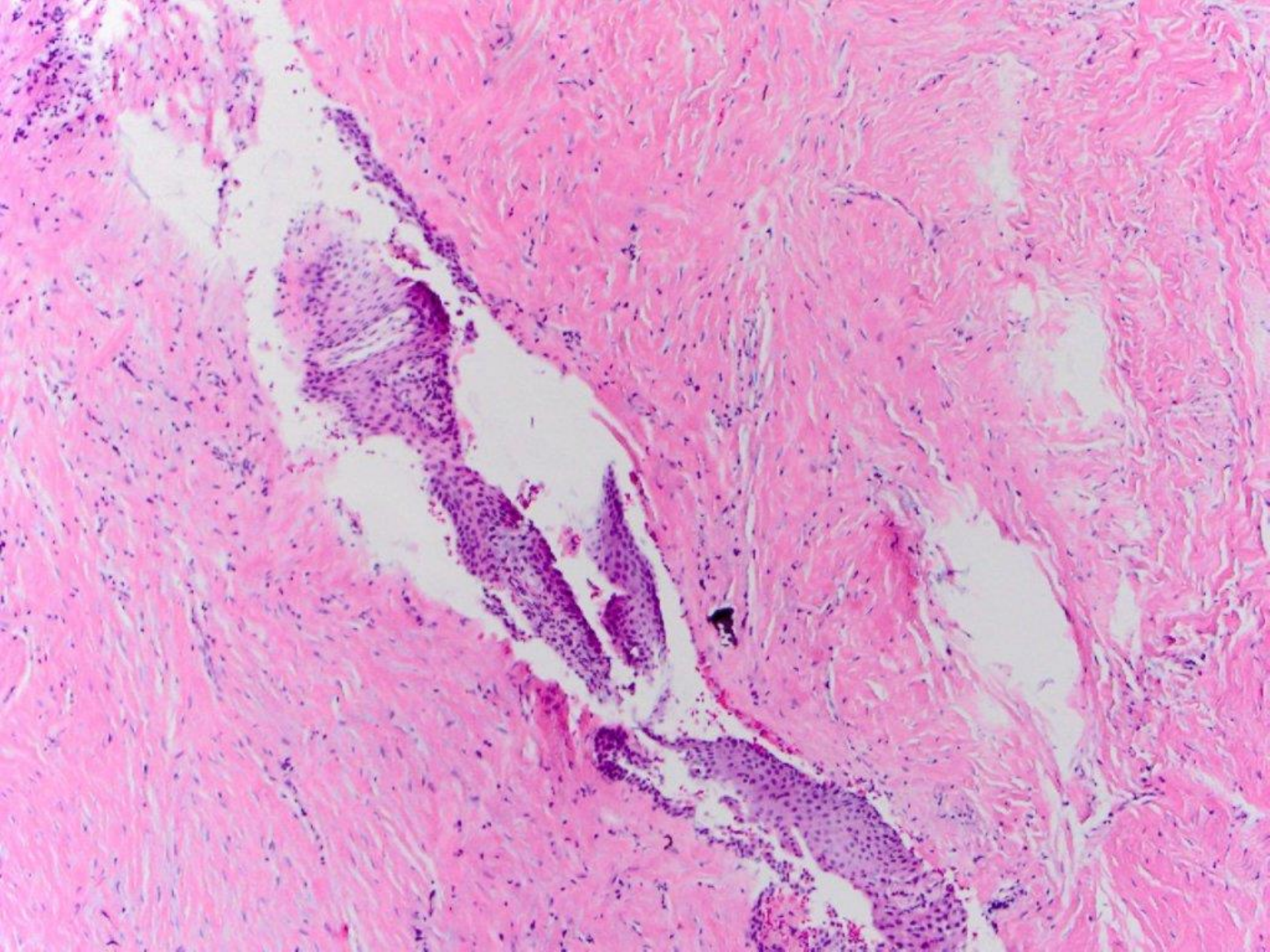


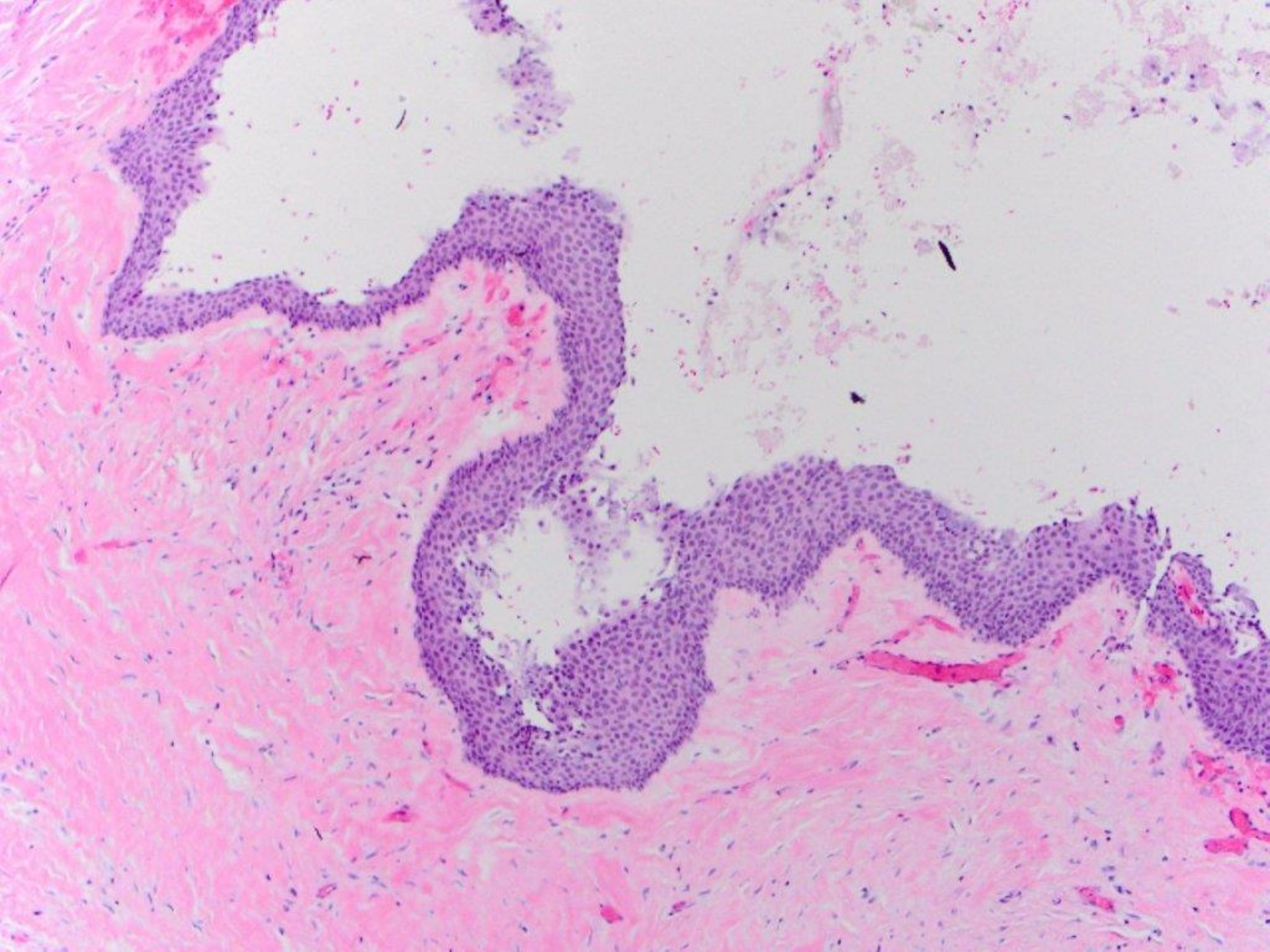


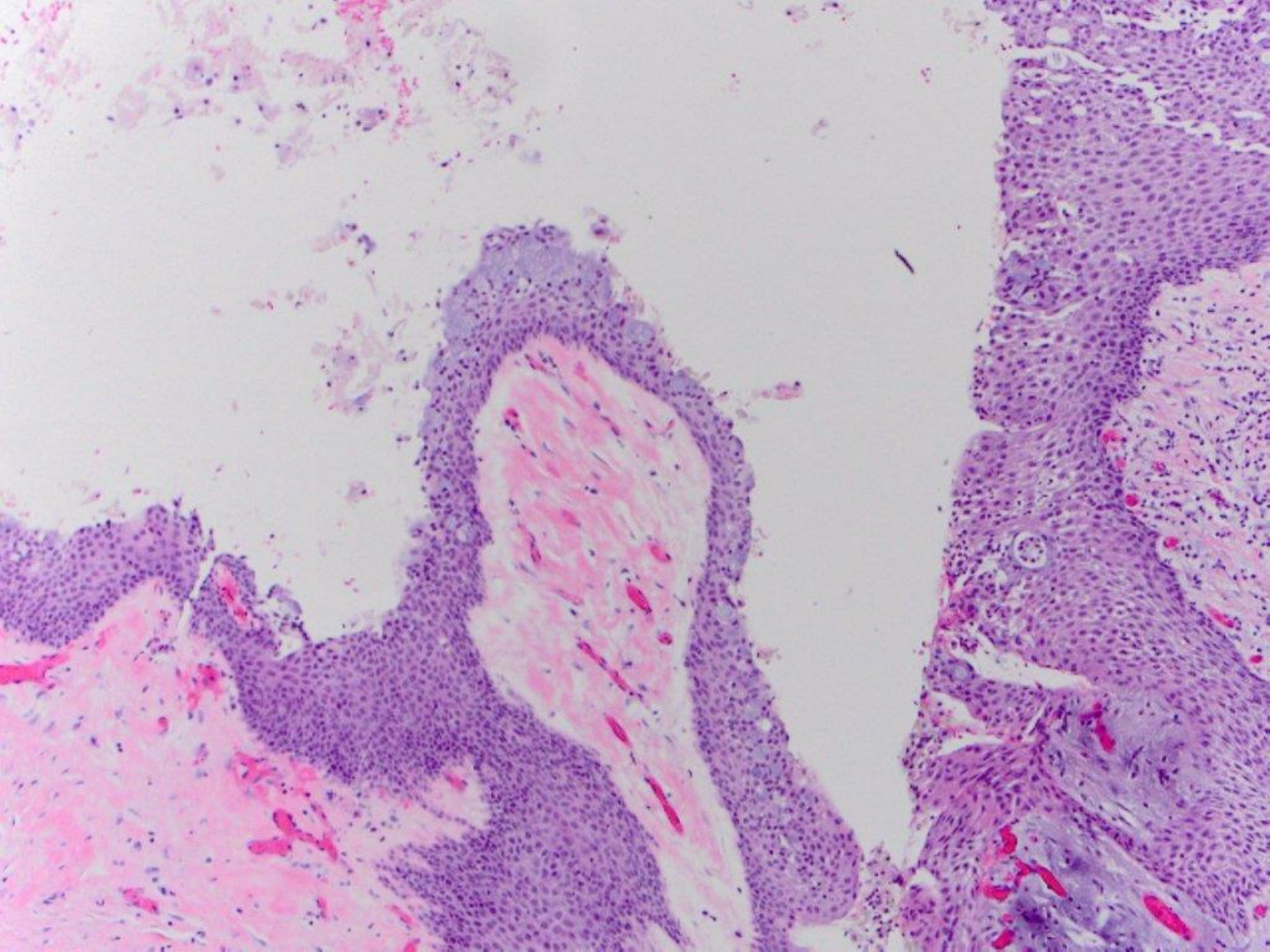


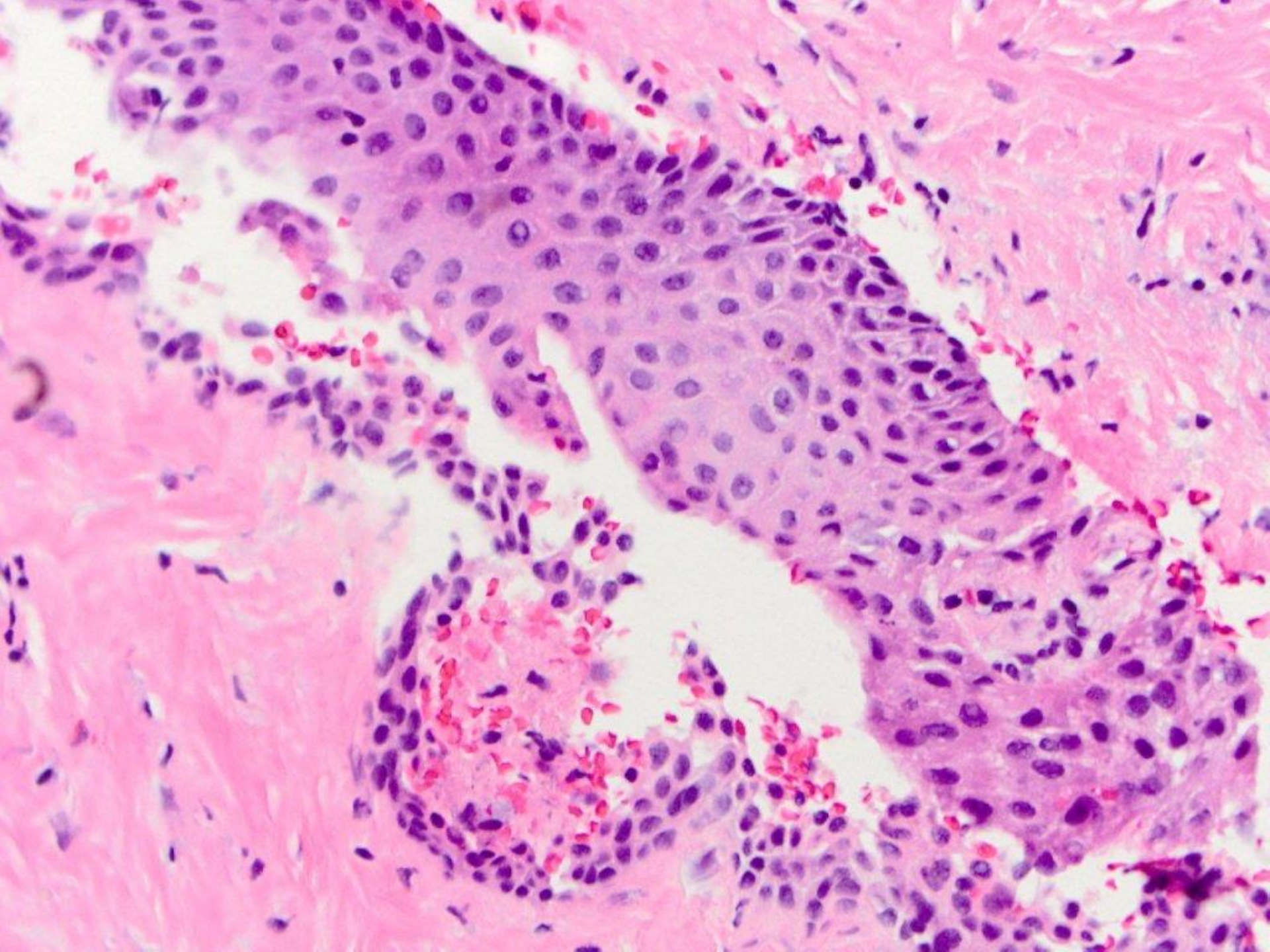
glandular odontogenic cyst (by frozen section)

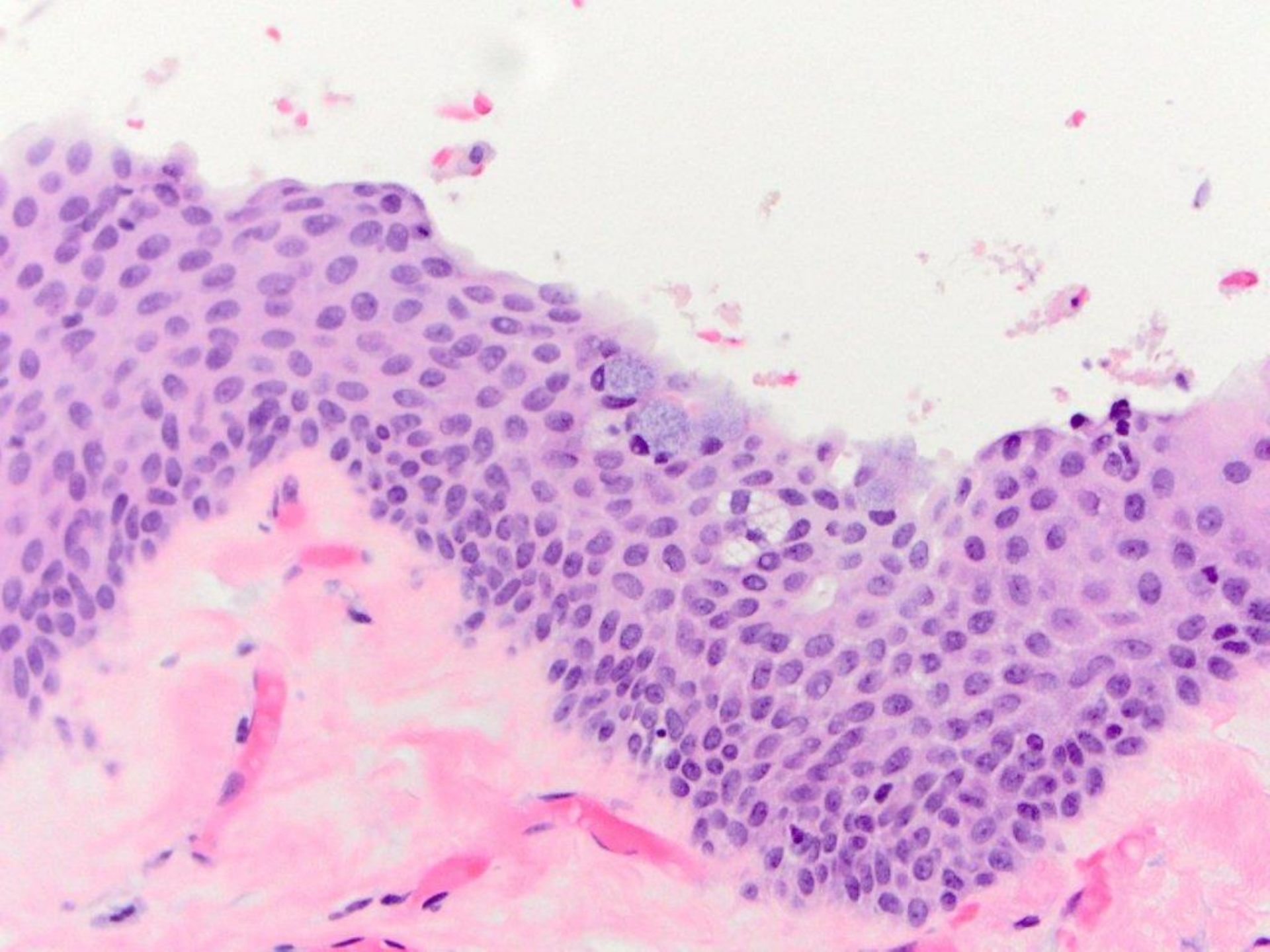


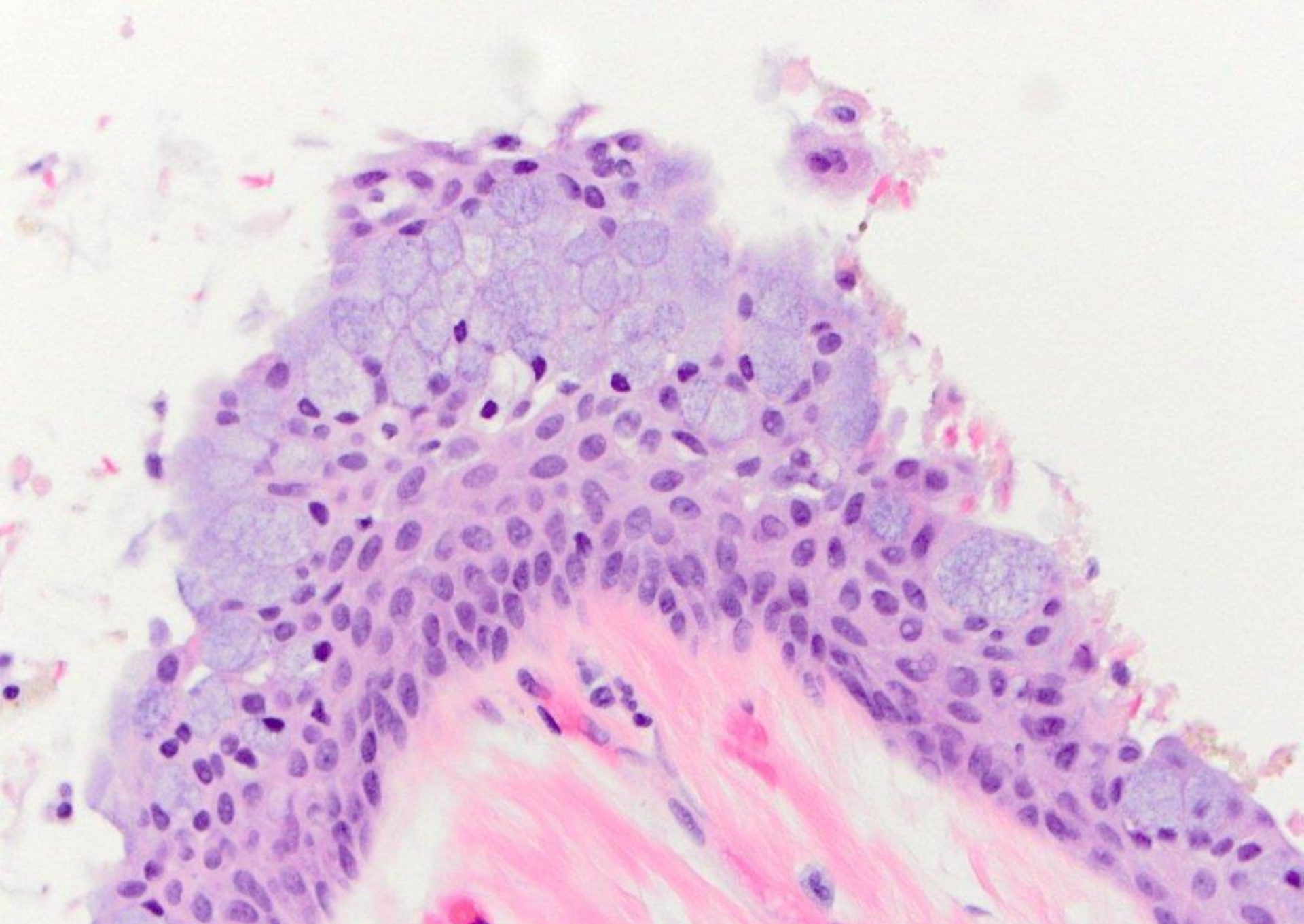




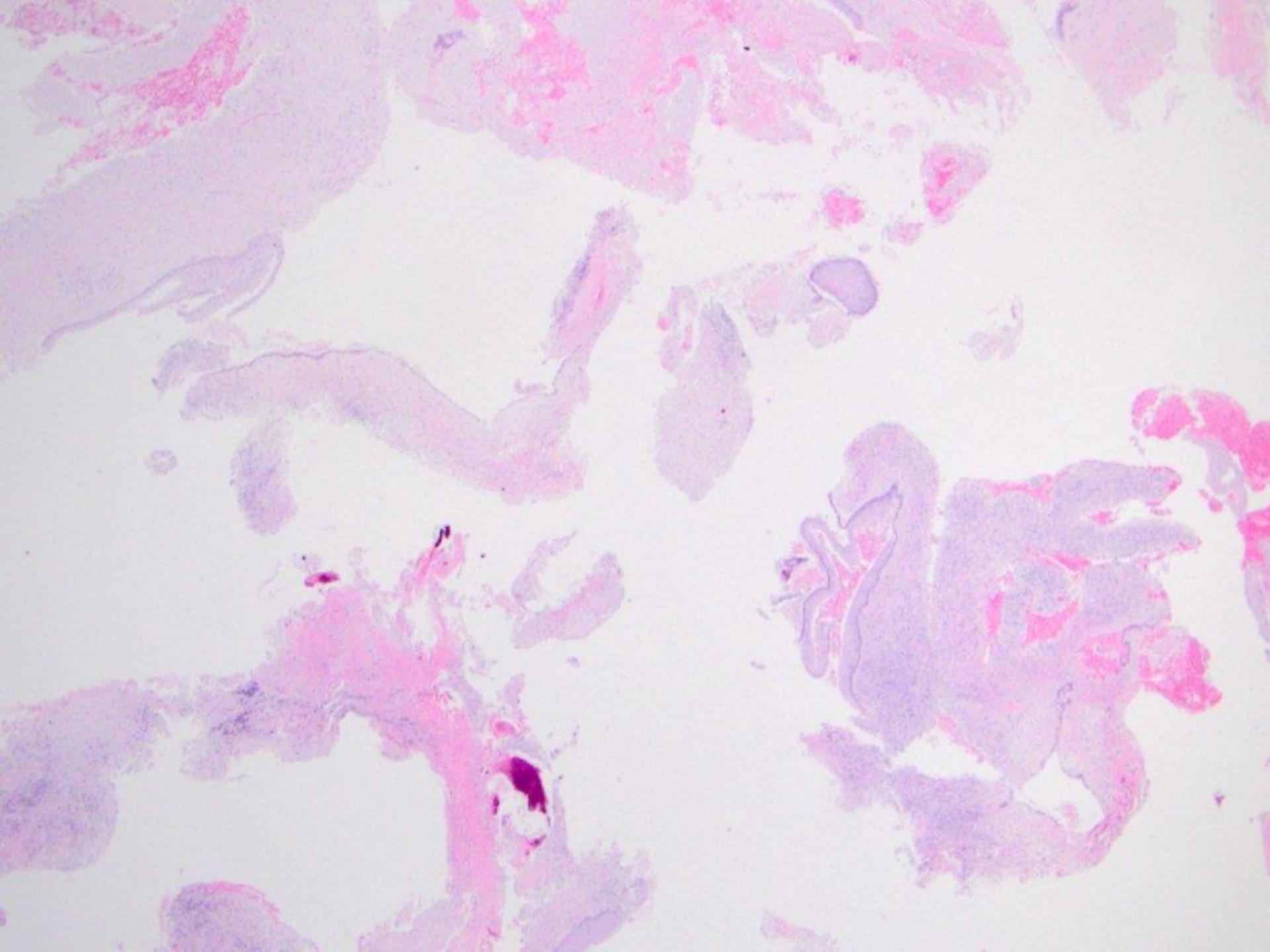


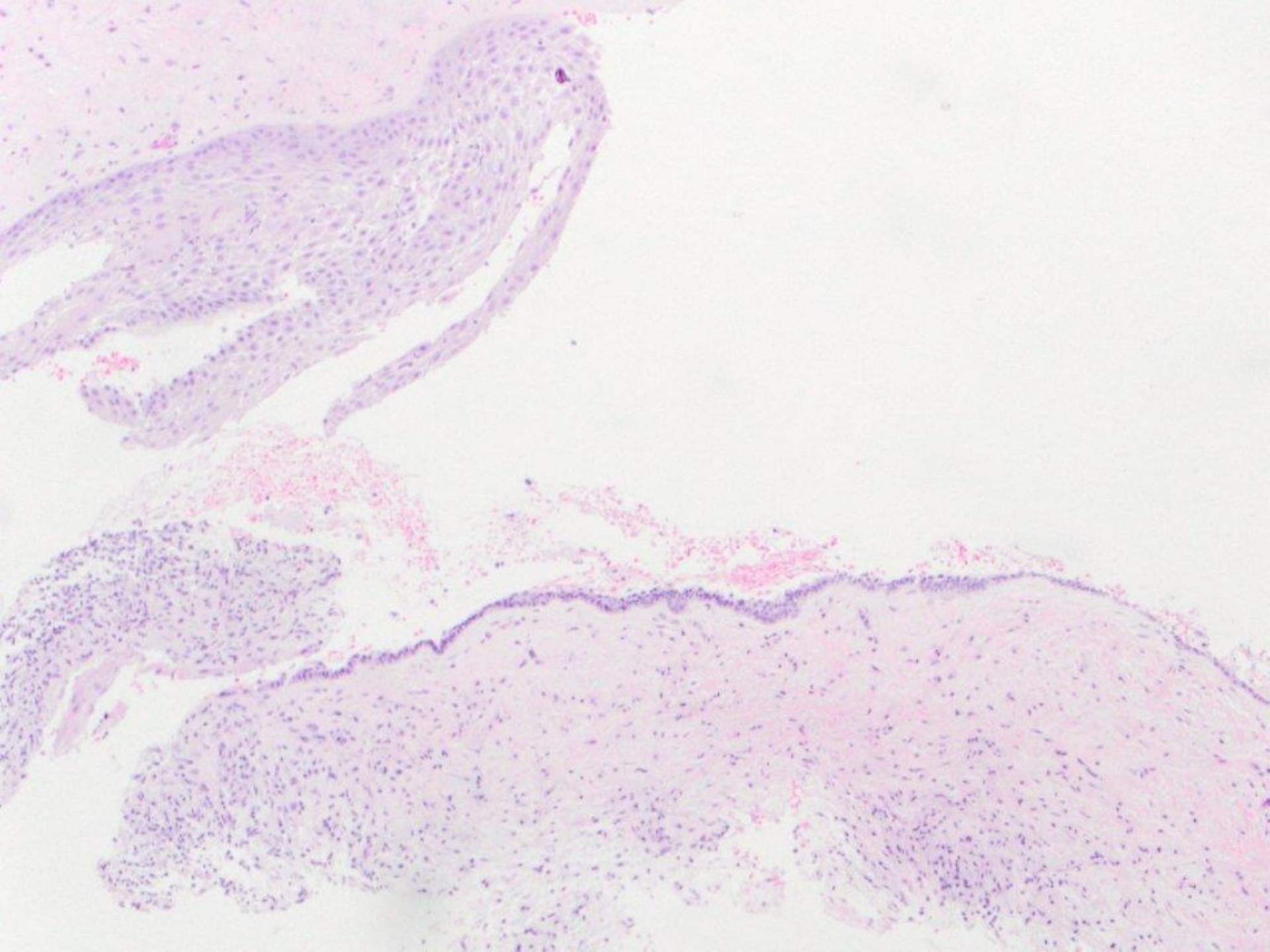


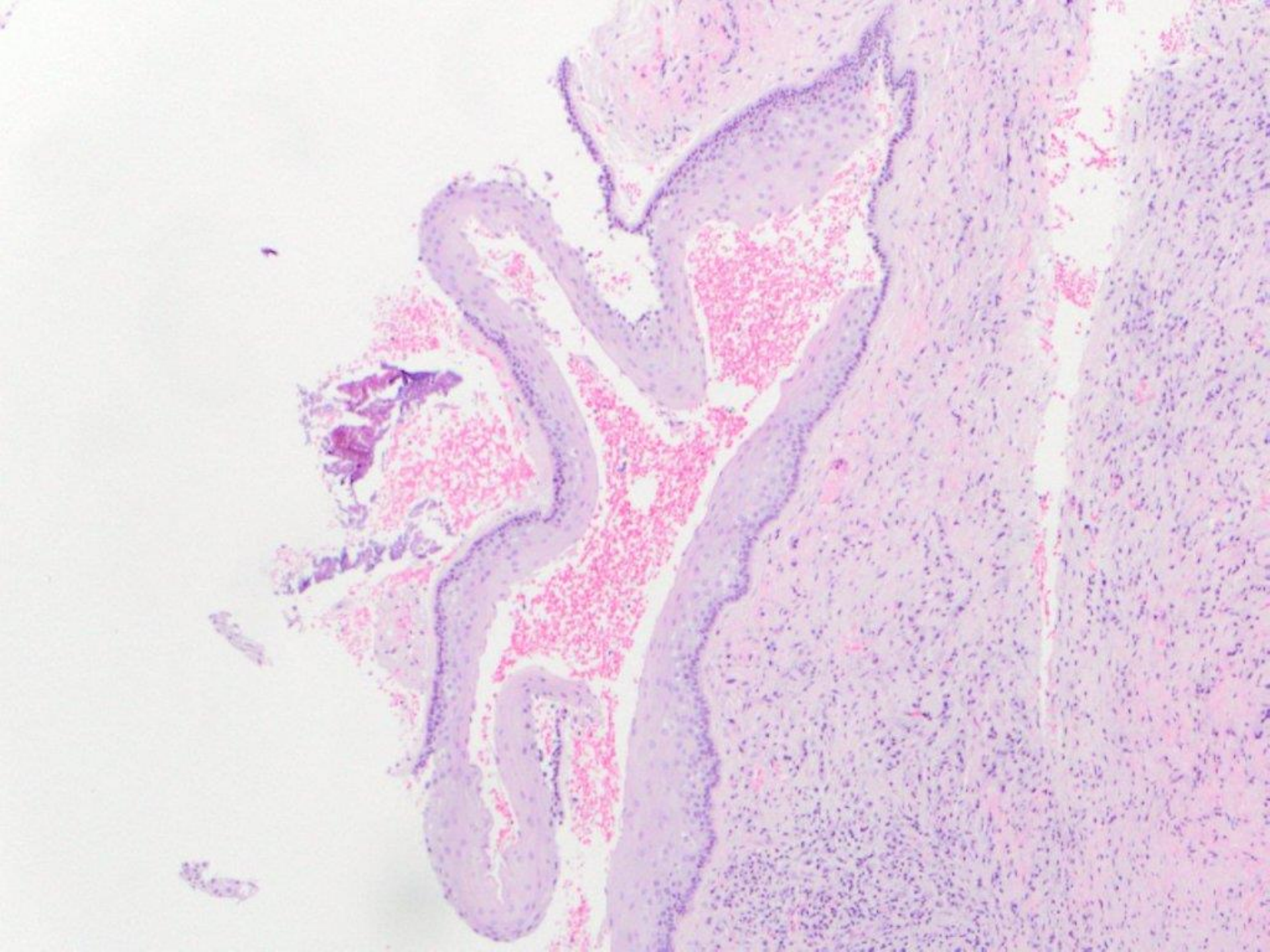


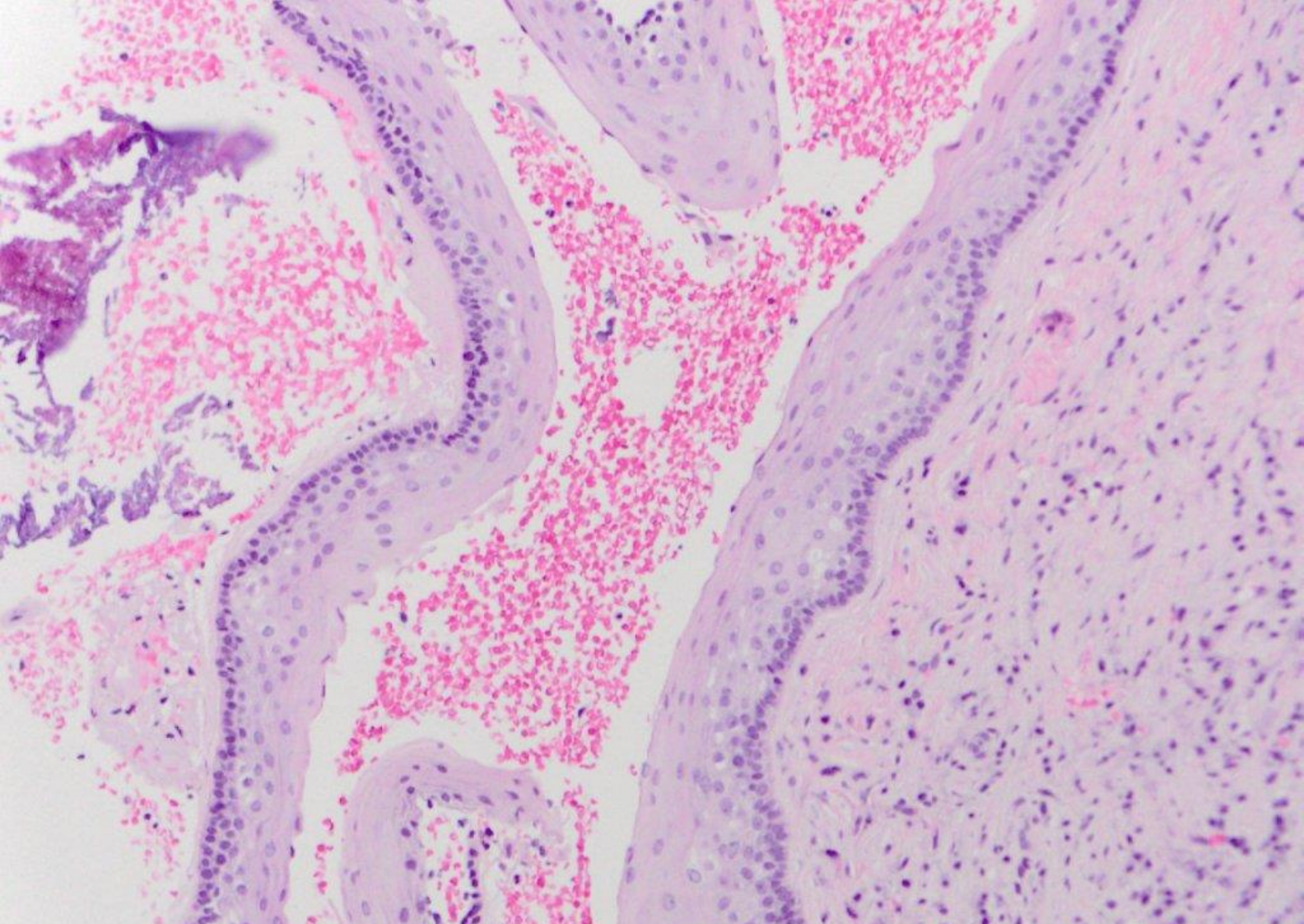


glandular odontogenic cyst



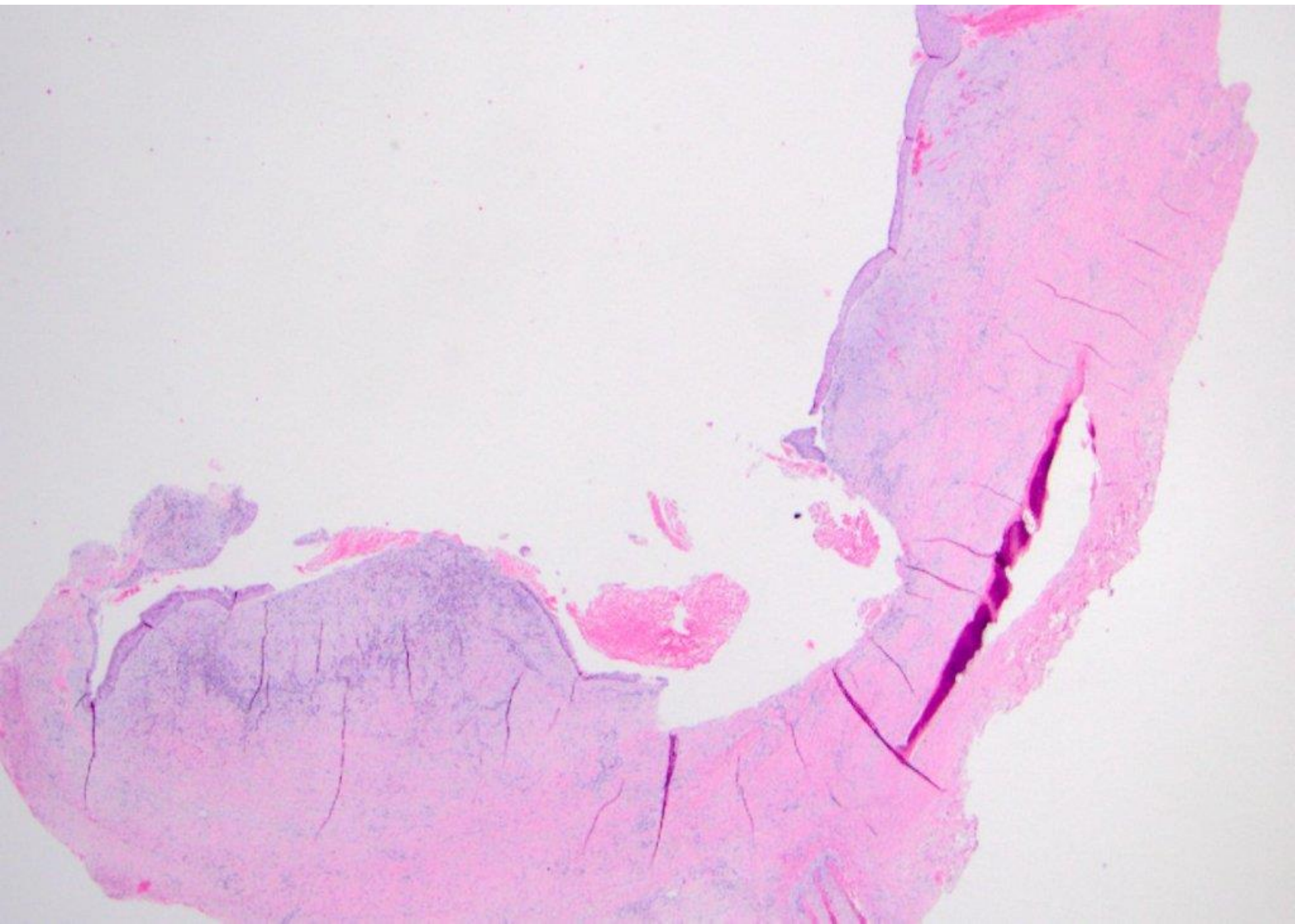


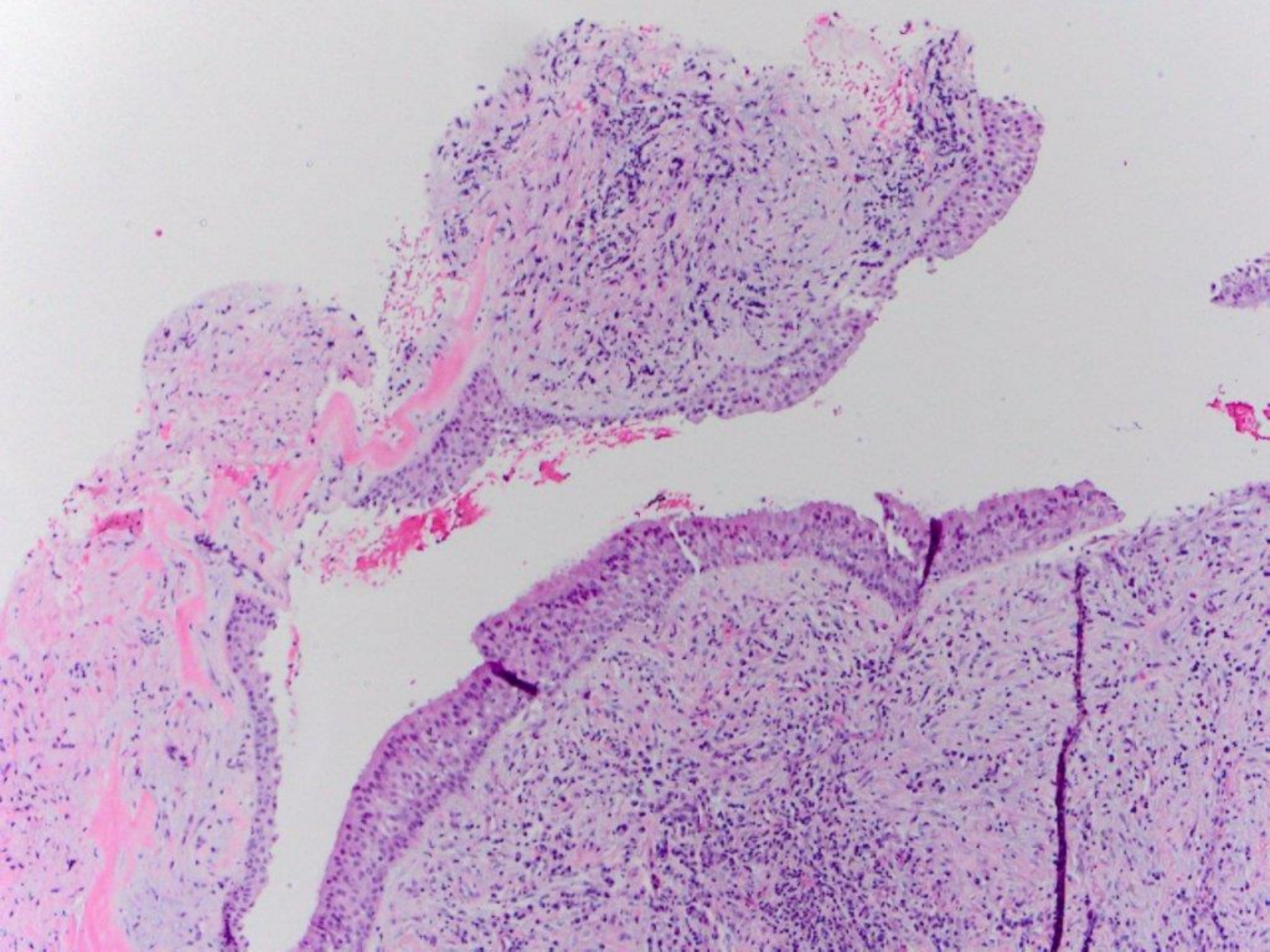


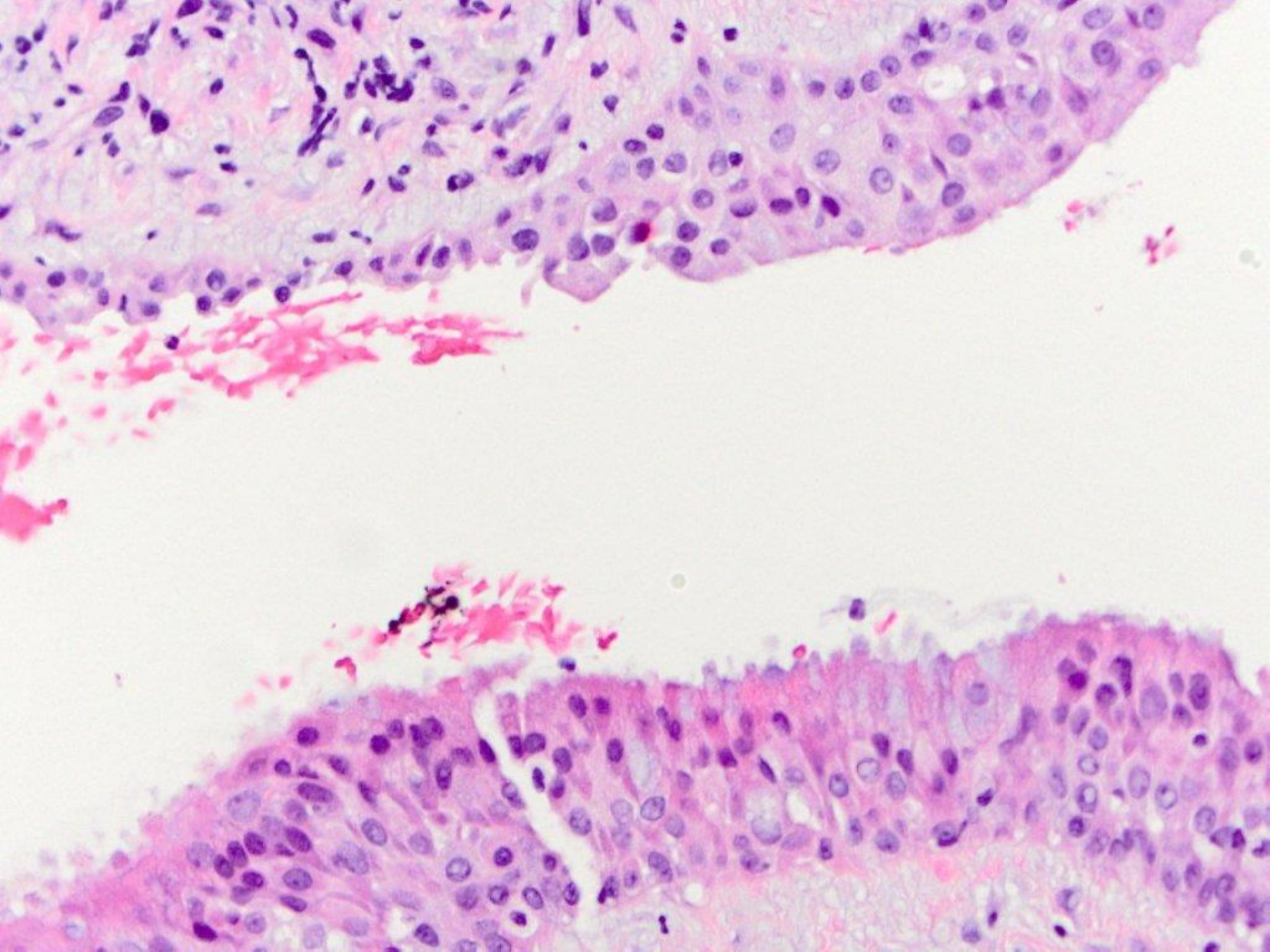


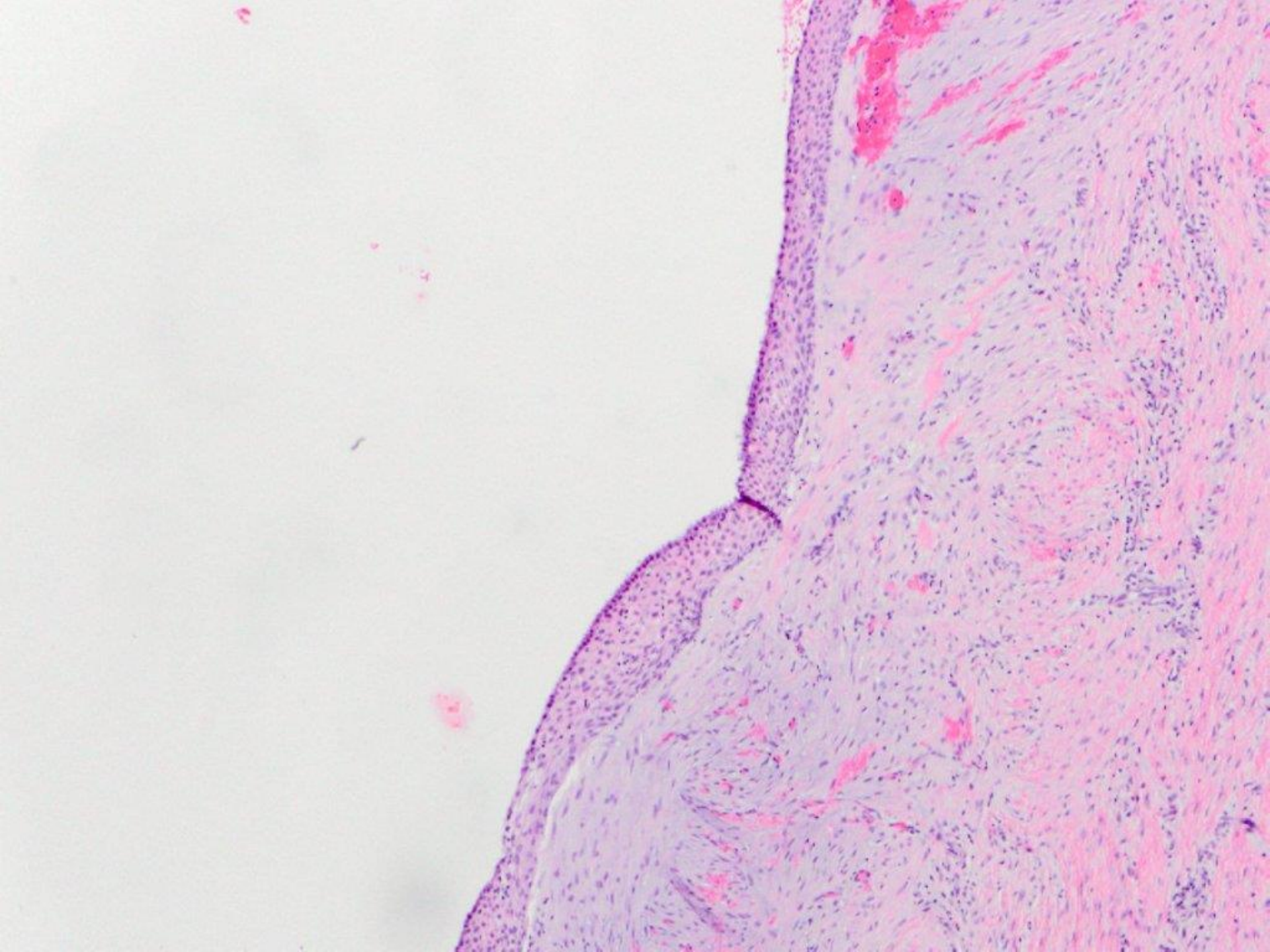
odontogenic keratocyst (keratocystic odontogenic tumor)

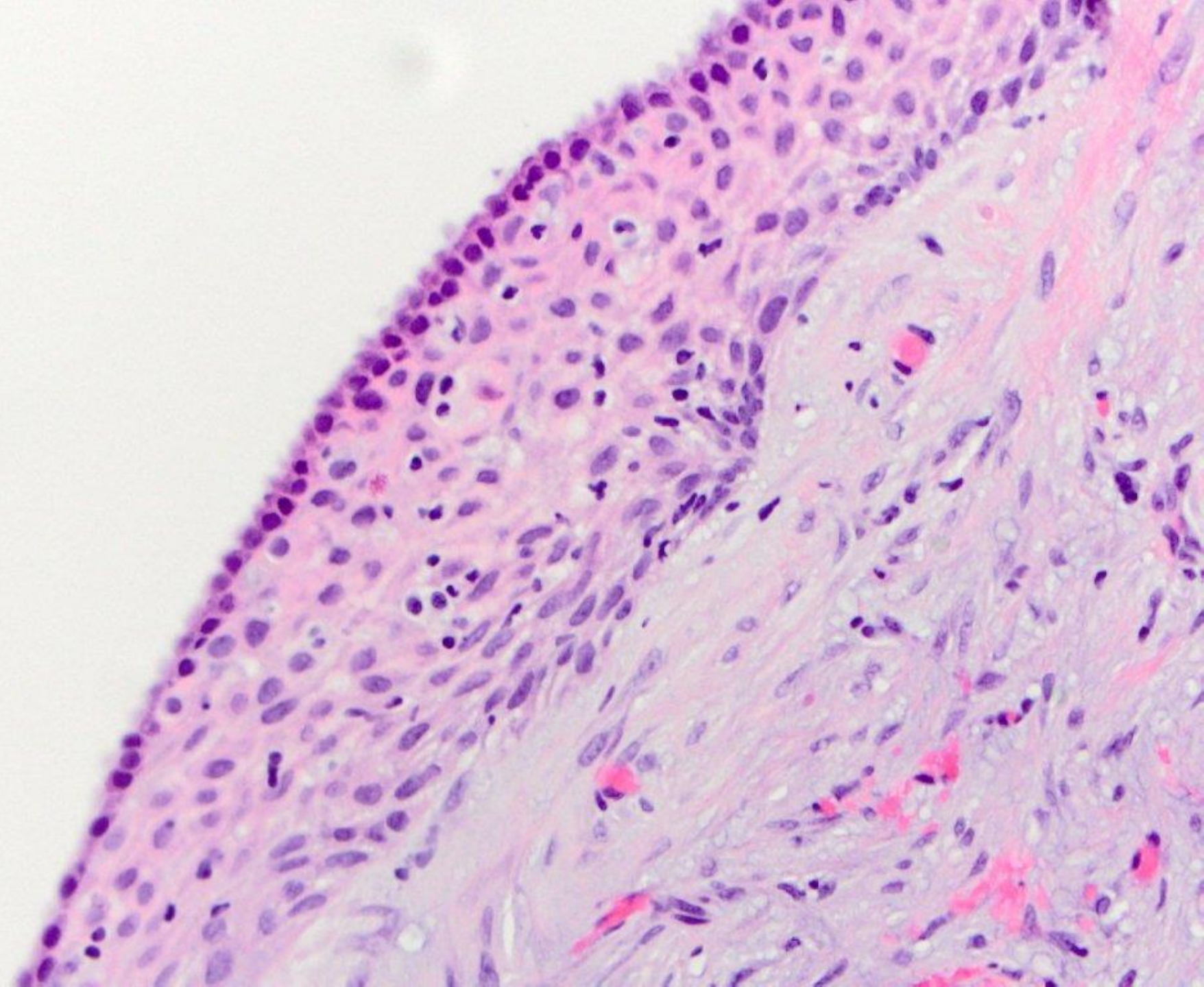
midline, anterior palate

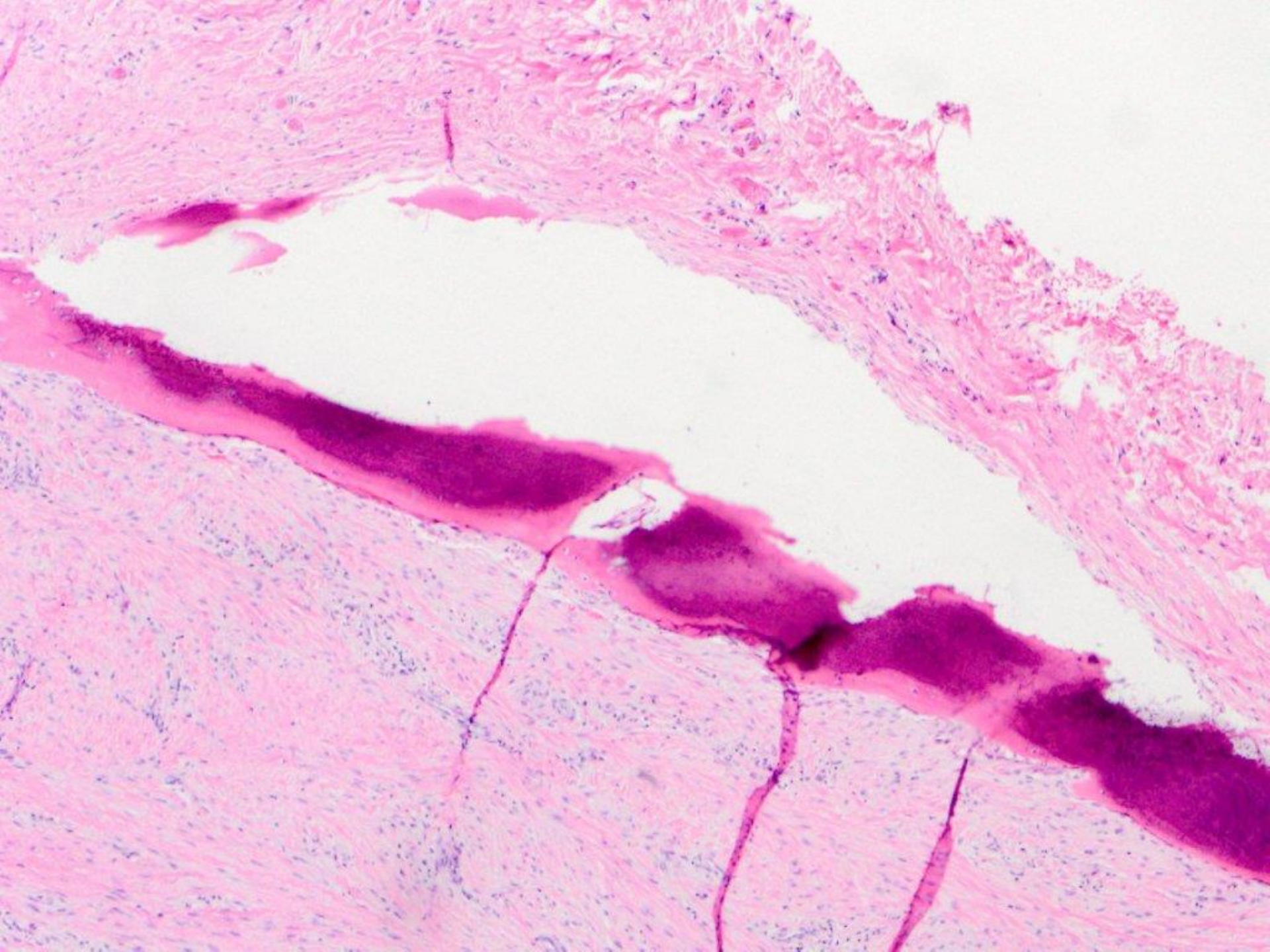


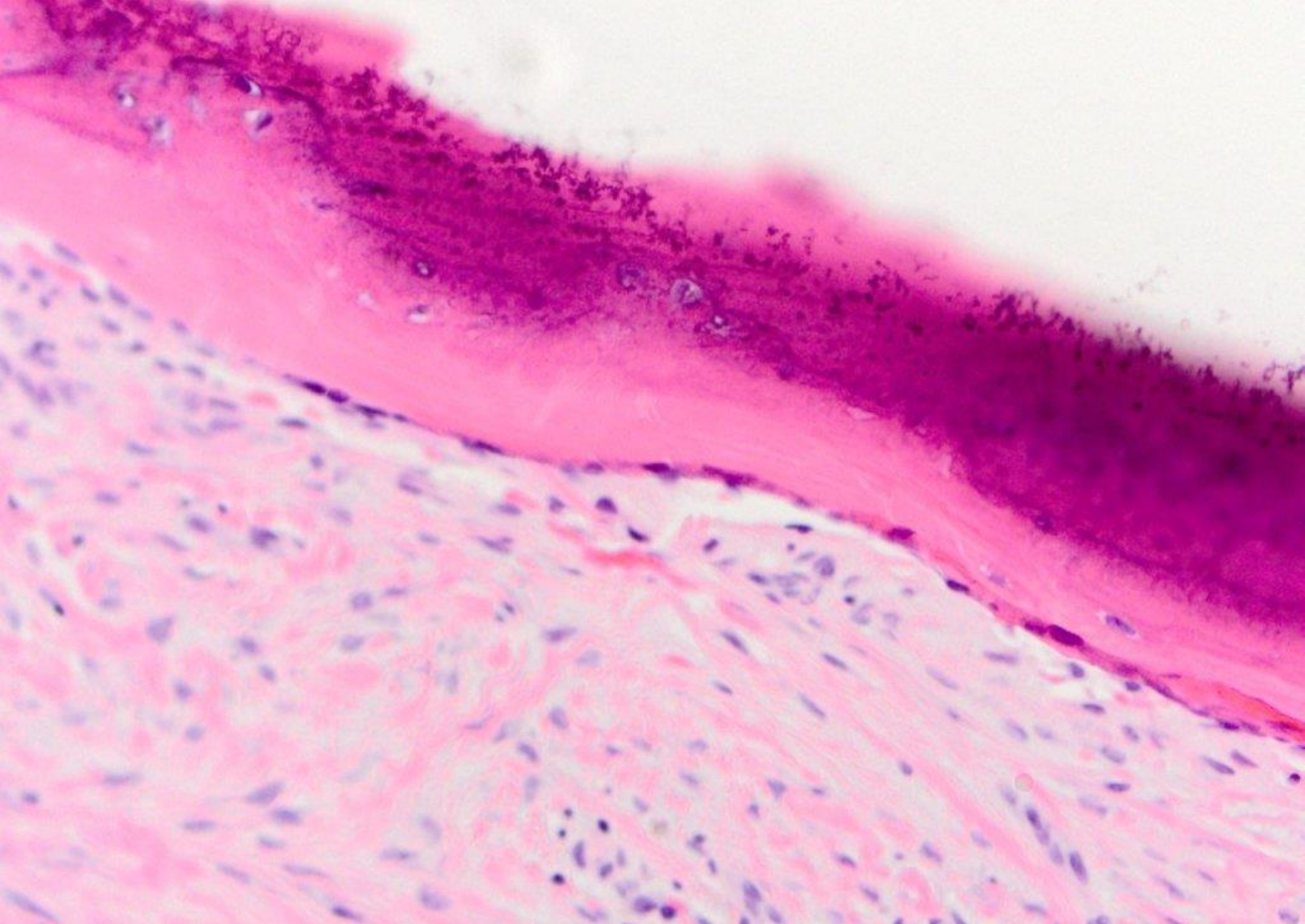












Nasopalatine duct cyst